

NEEDLE IN A HAY STACK

DR BINOY JOHN

MD DM (CARDIOLOGY) FESC FSCAI FAPSIC

CHIEF:

DEPARTMENT OF ADULT CARDIOLOGY &
INTERVENTIONAL CARDIOLOGY

MIOT INTERNATIONAL, CHENNAI, INDIA

NIC@ TCTAP 2014; SEOUL; S KOREA

60 YEAR OLD

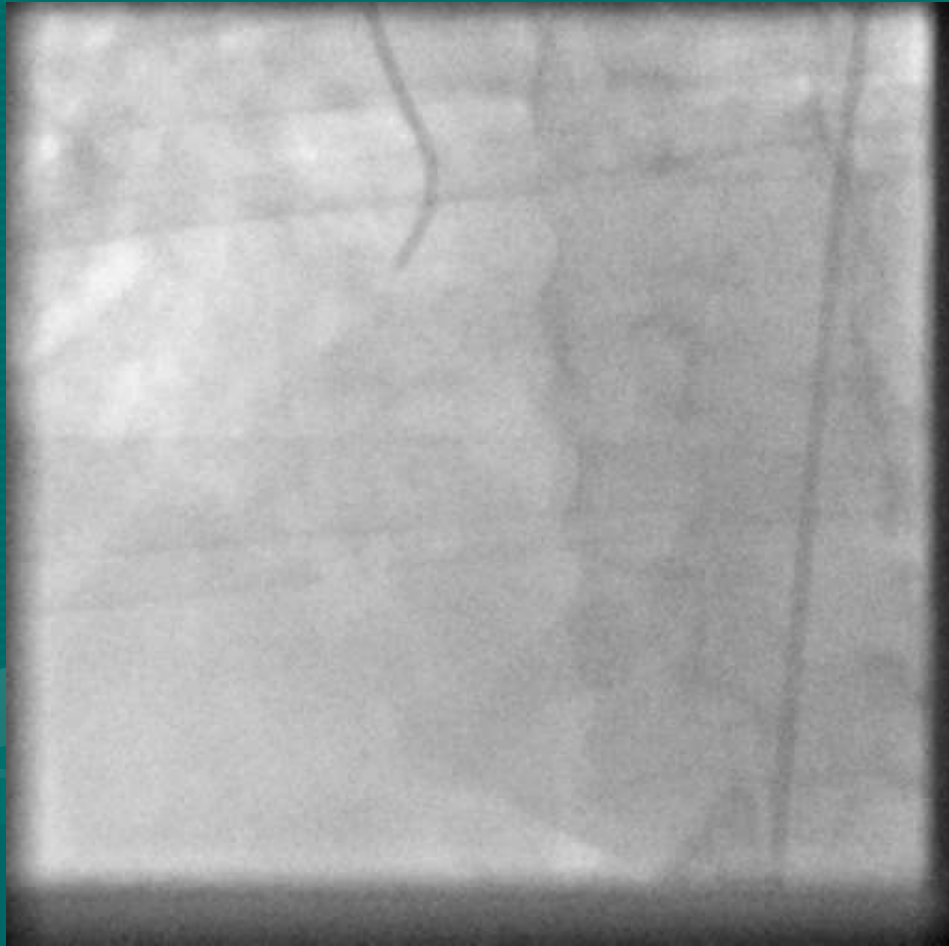
DIABETIC

S.Cr 1.8

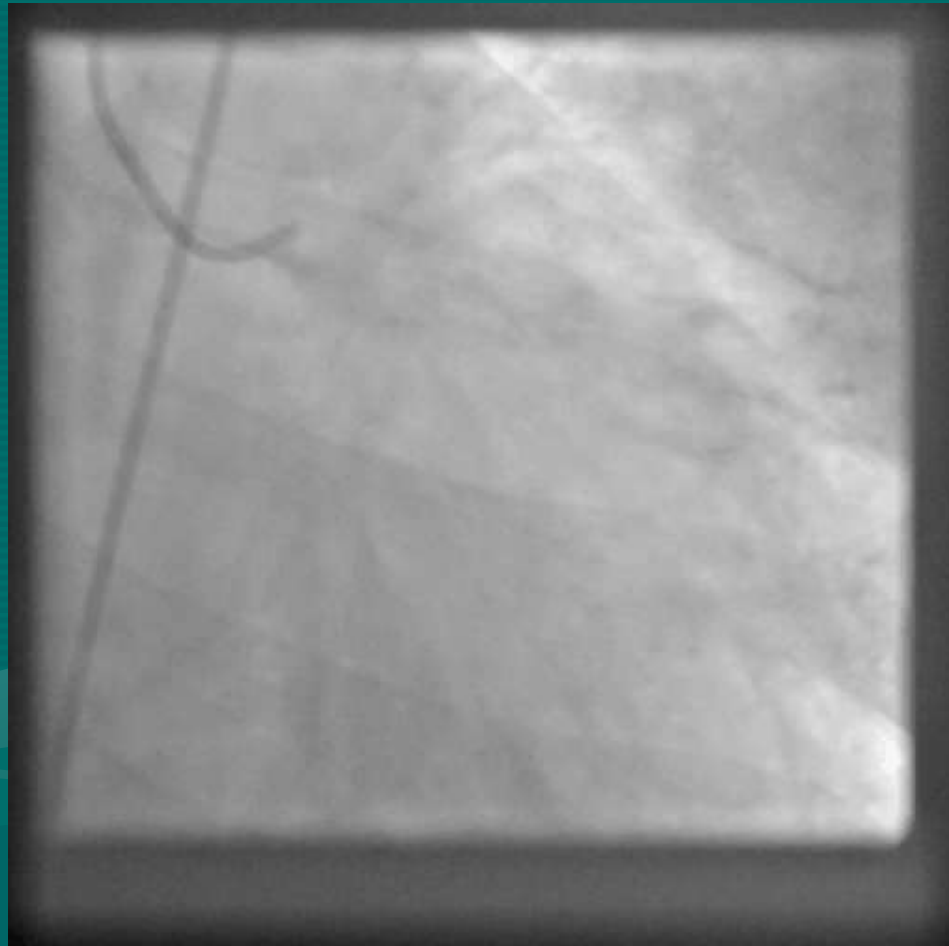
LV EF: 60%

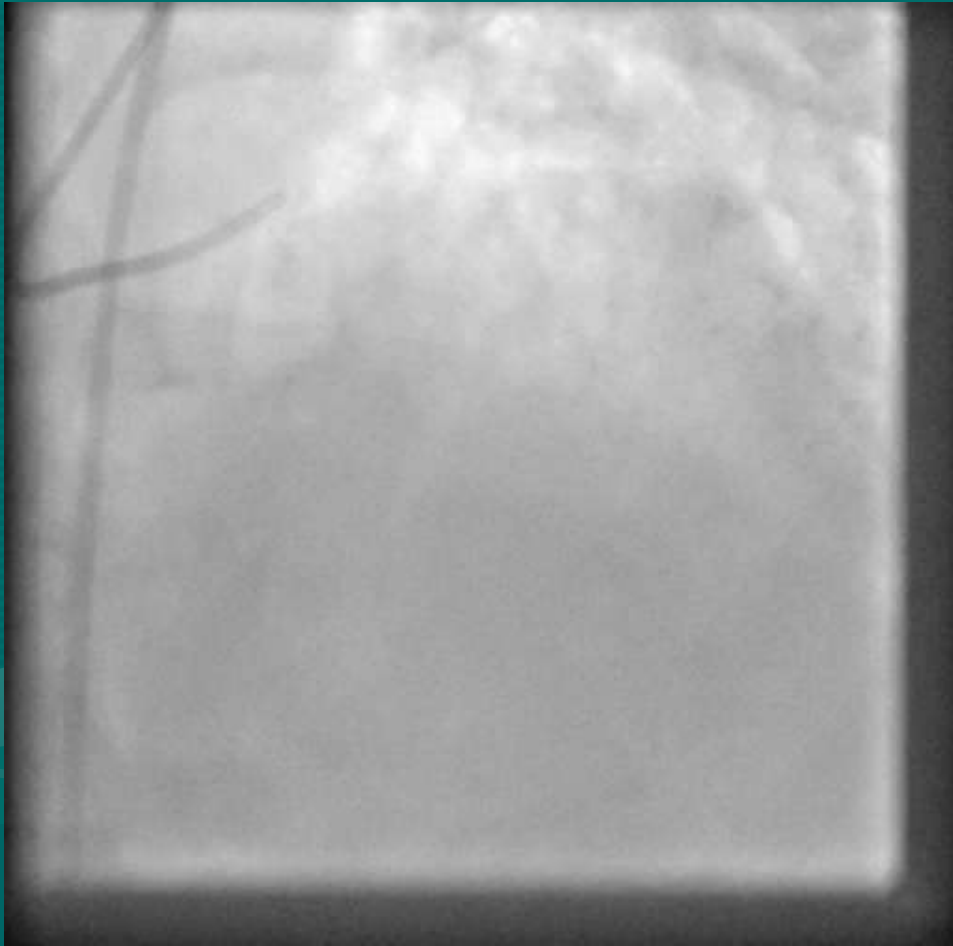


RCA

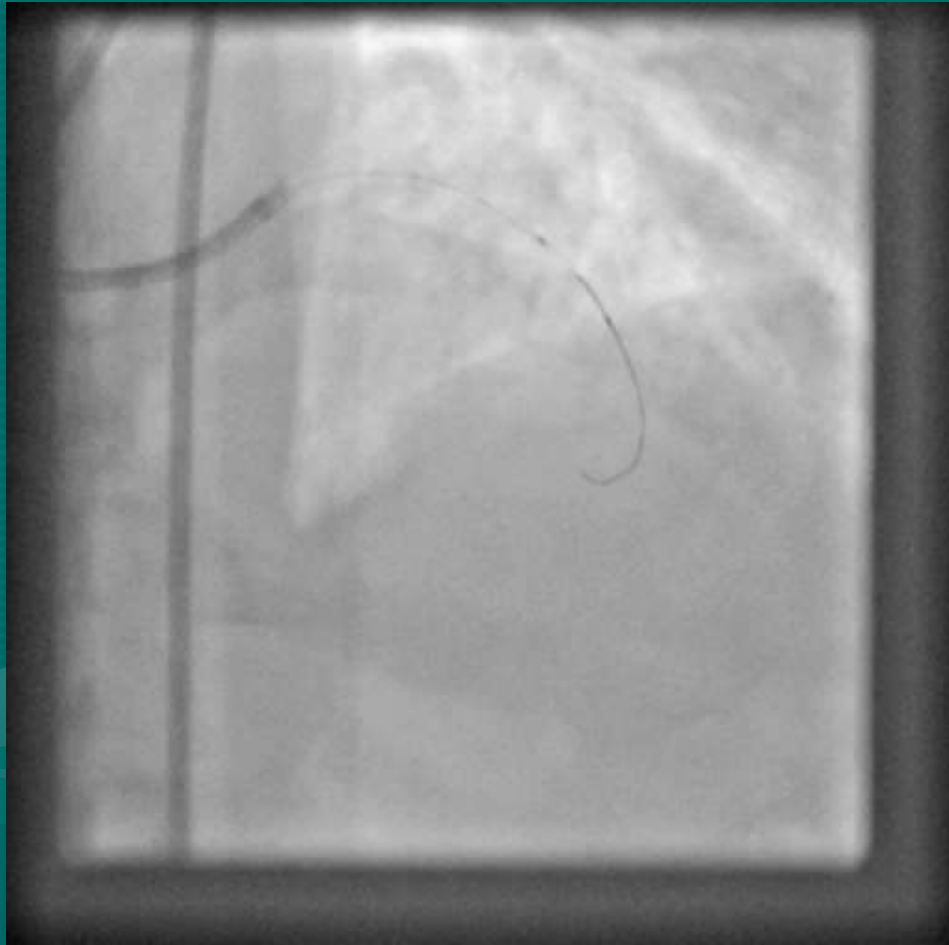


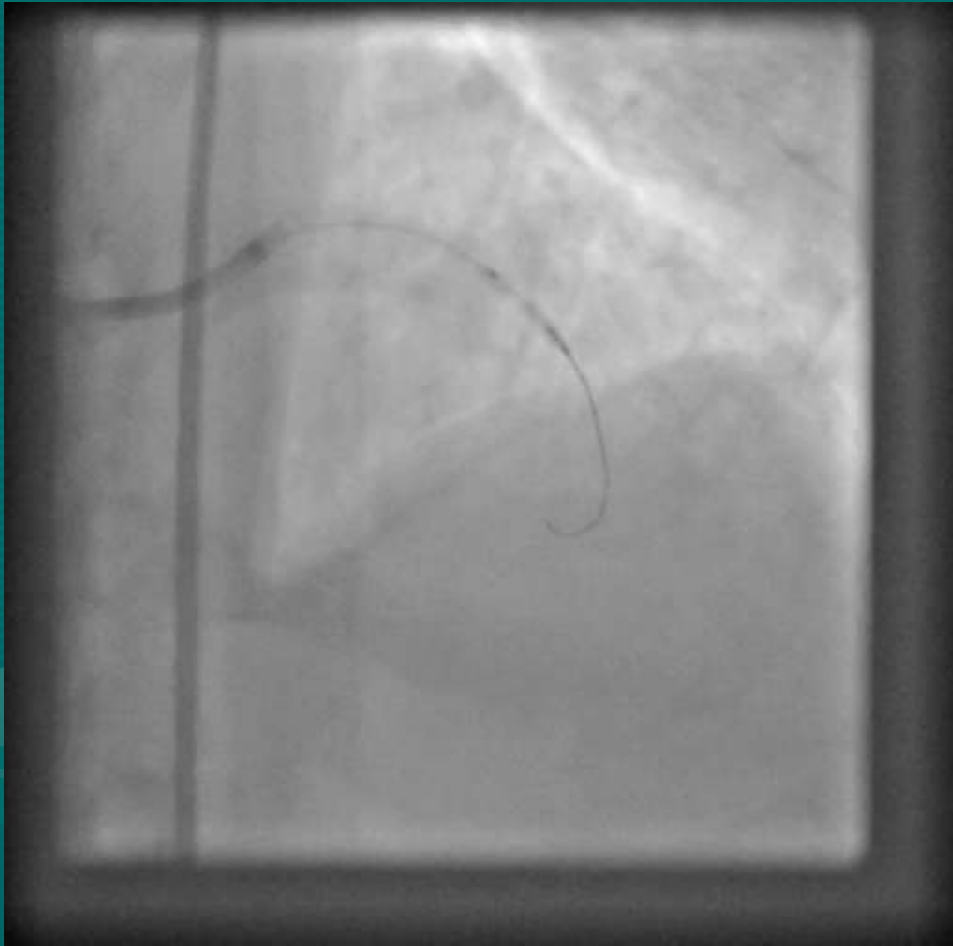
LEFT SYSTEM

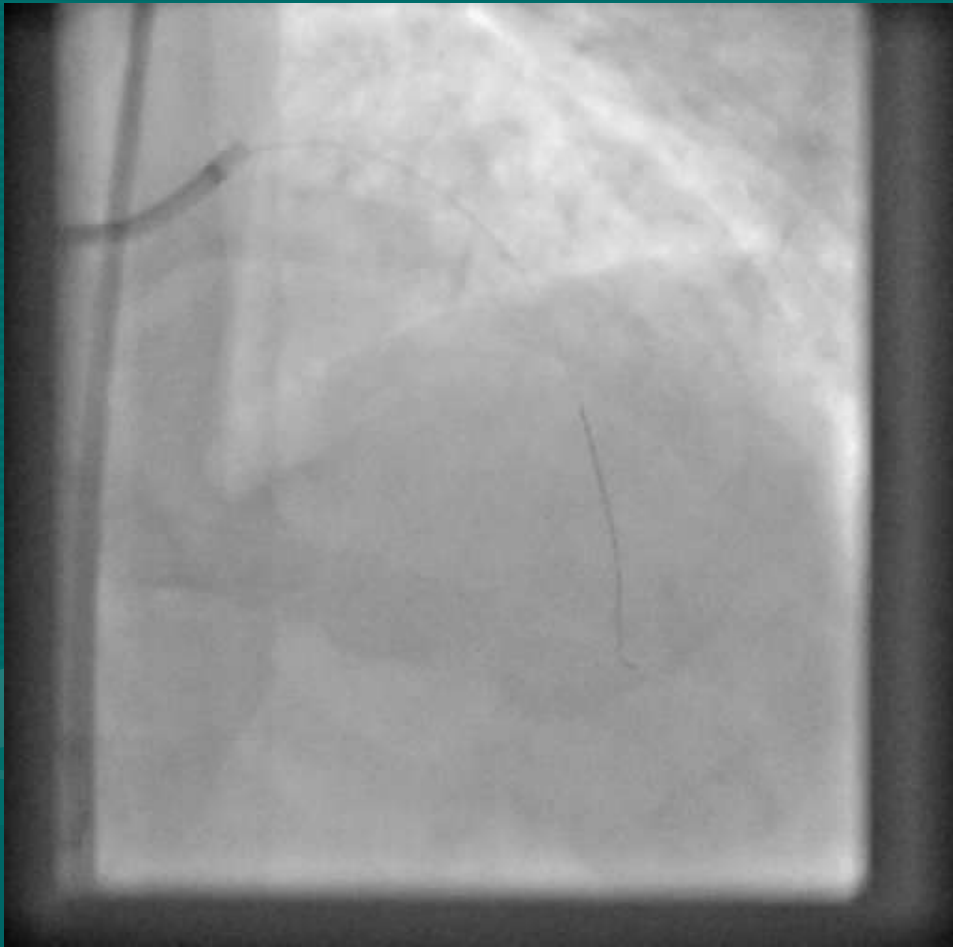




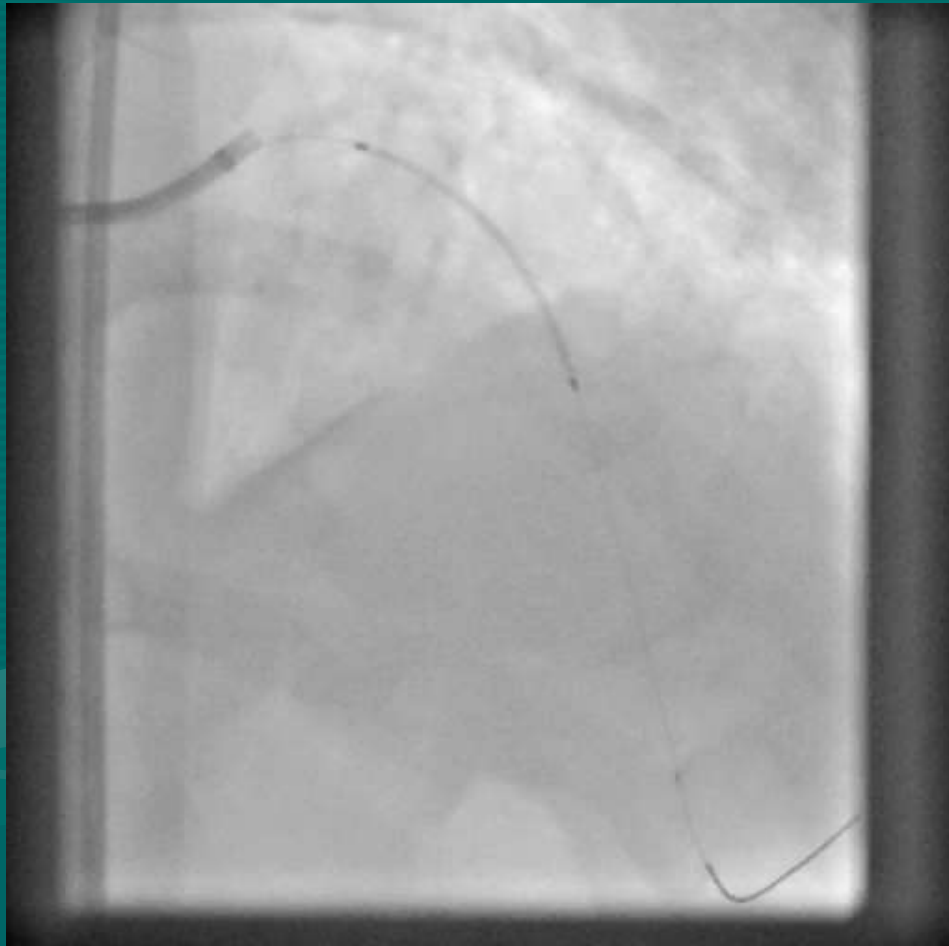
2.0 X 12 TREK BALLOON

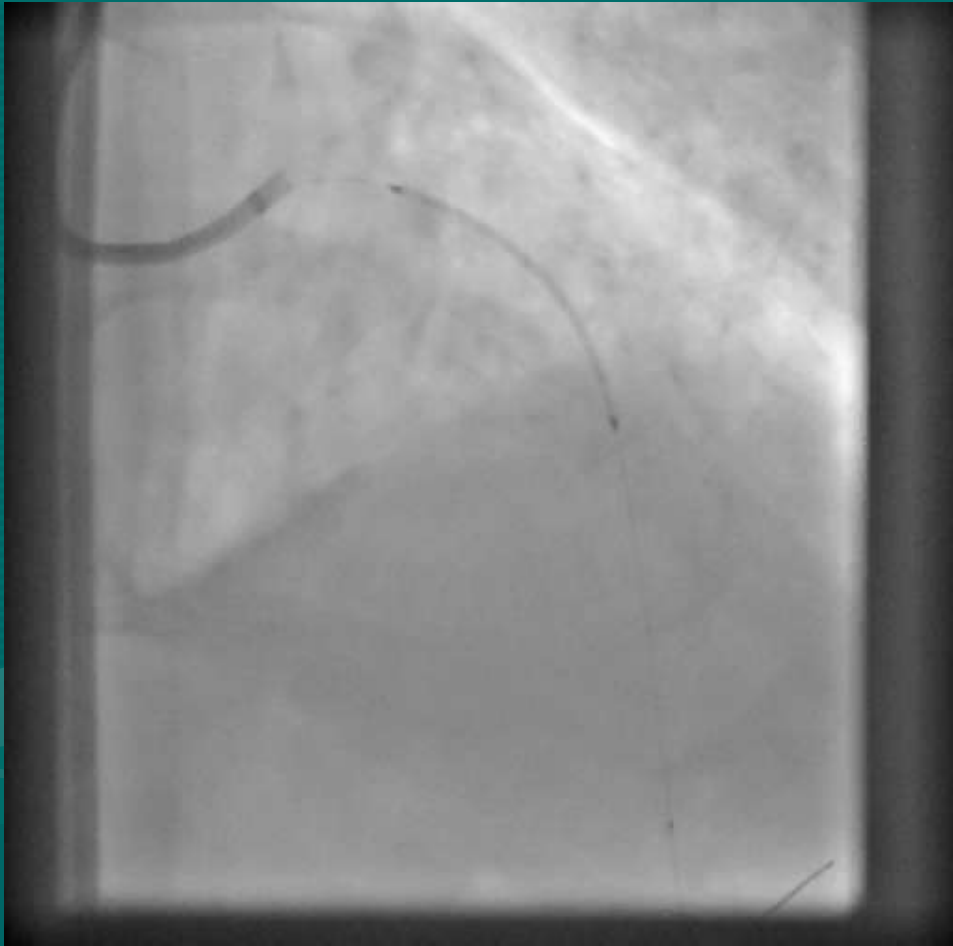


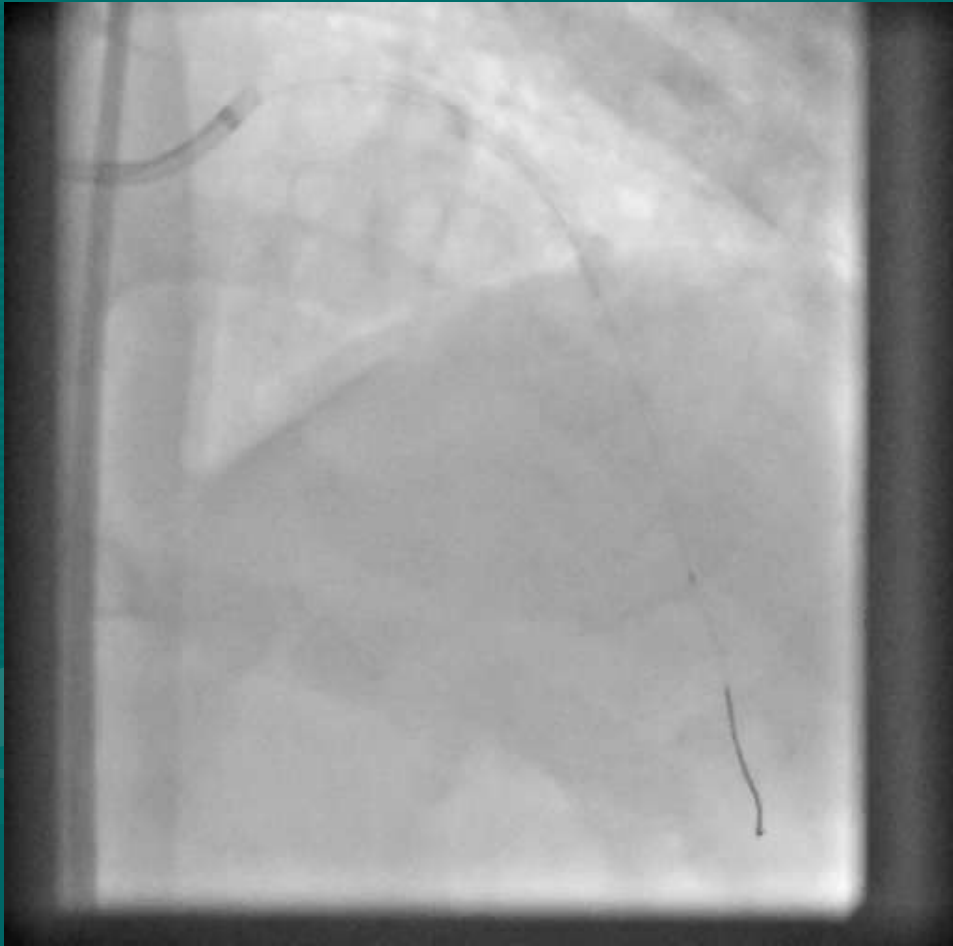


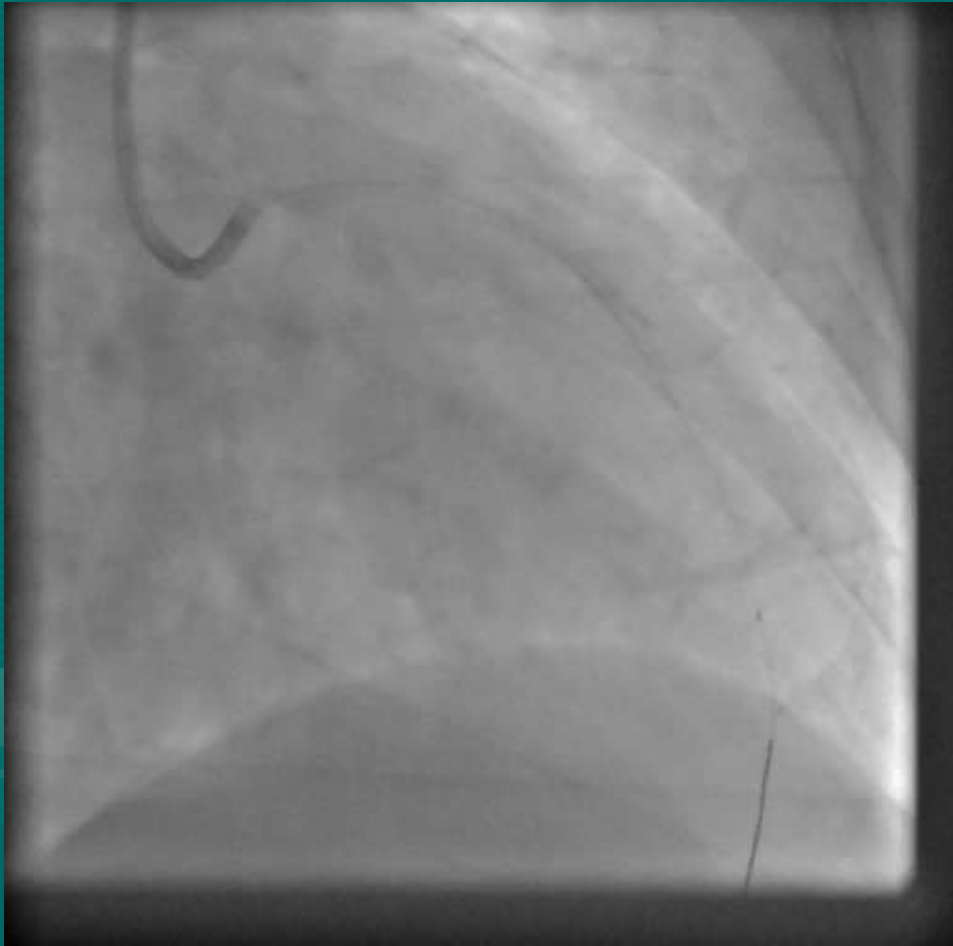


2.50 X 38 XIENCE PRIME

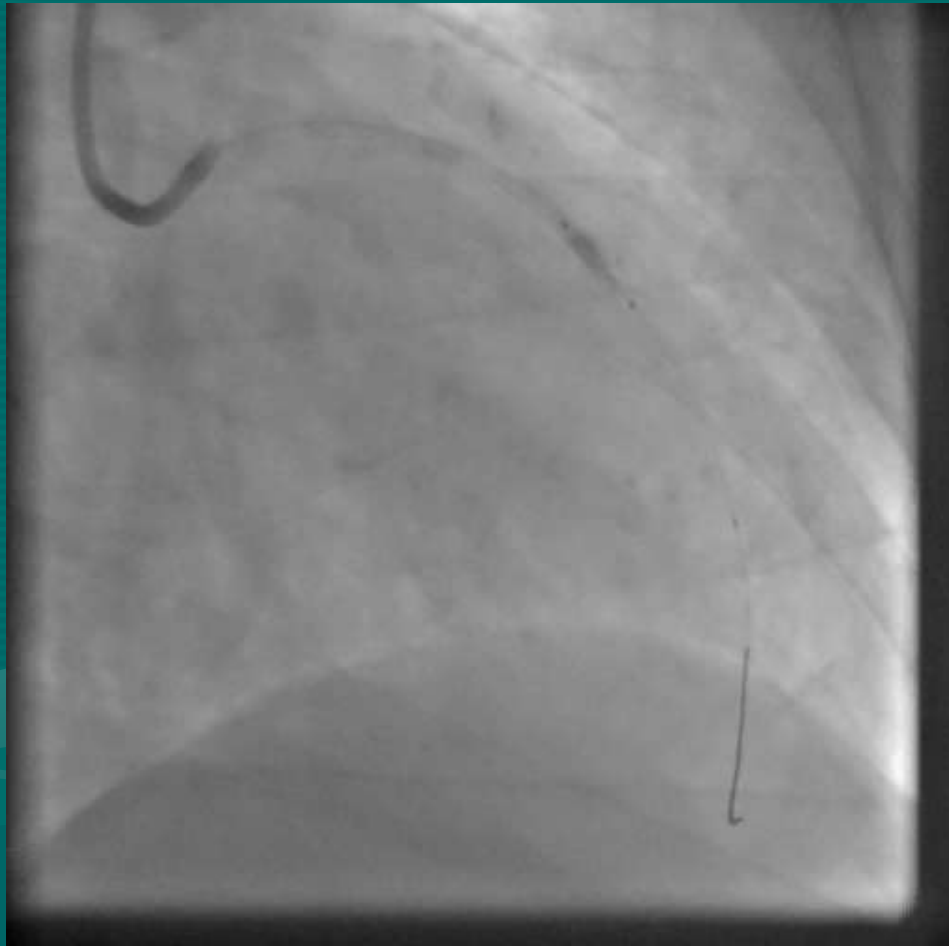


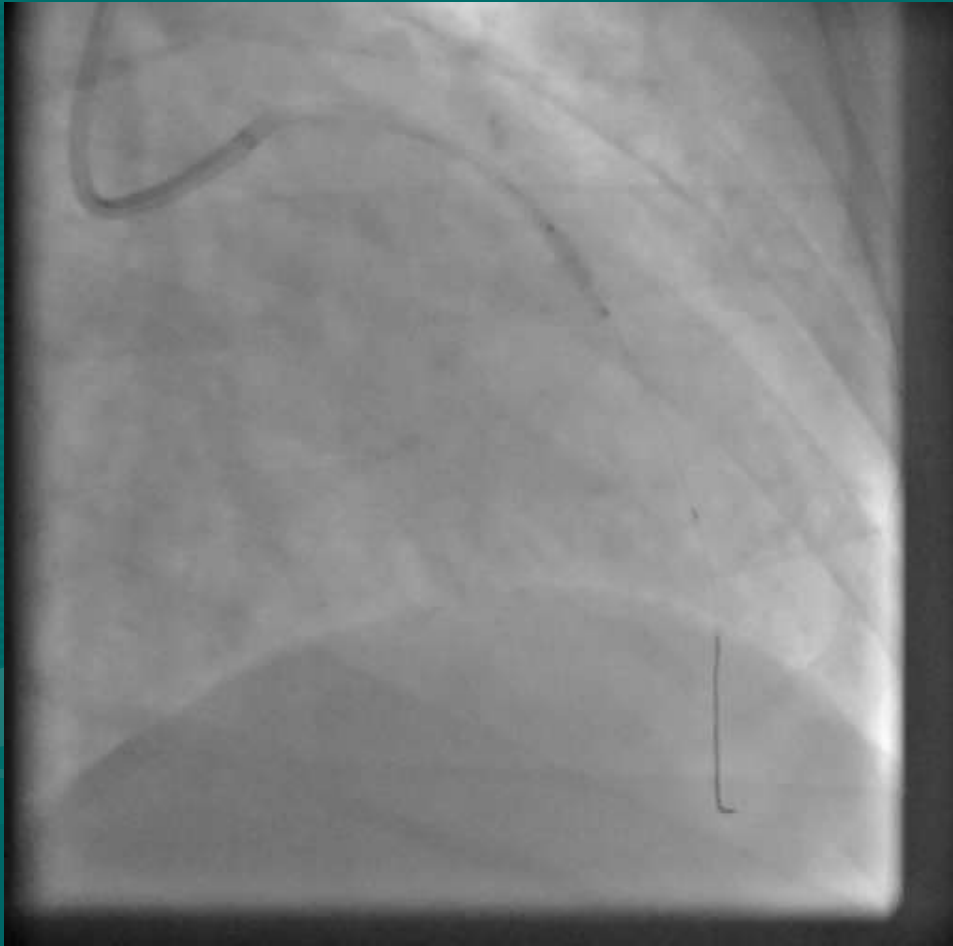


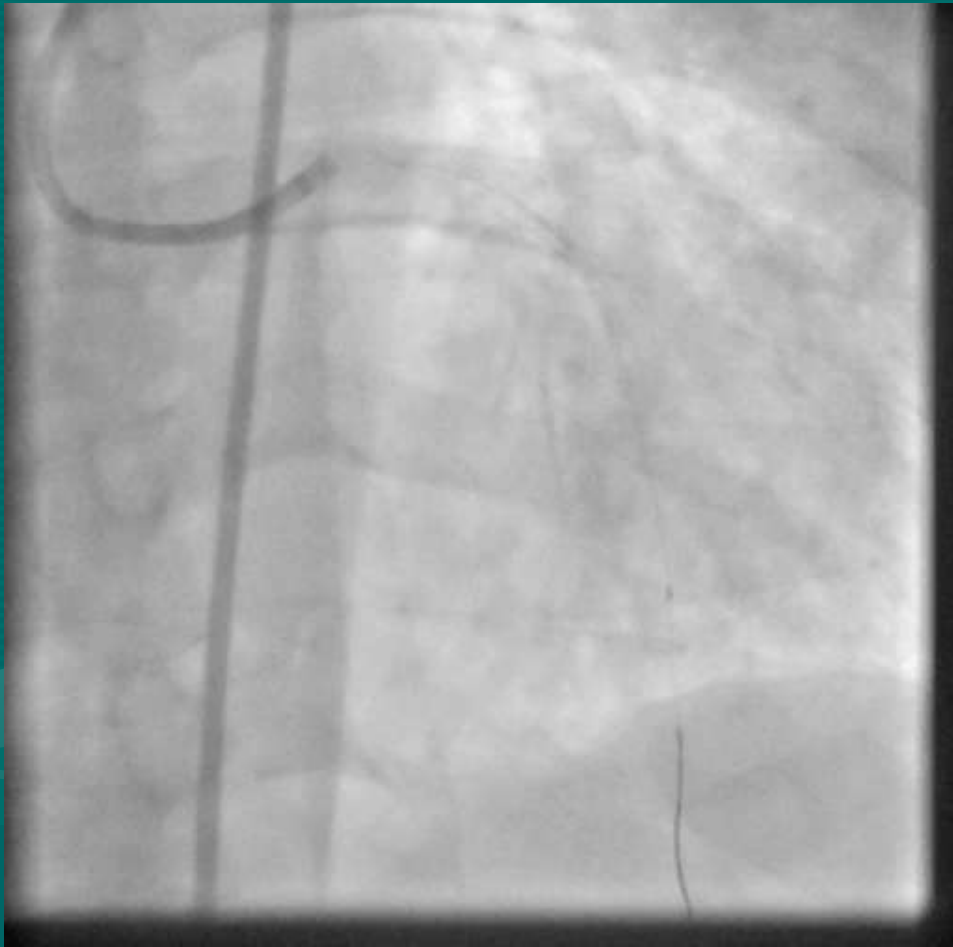




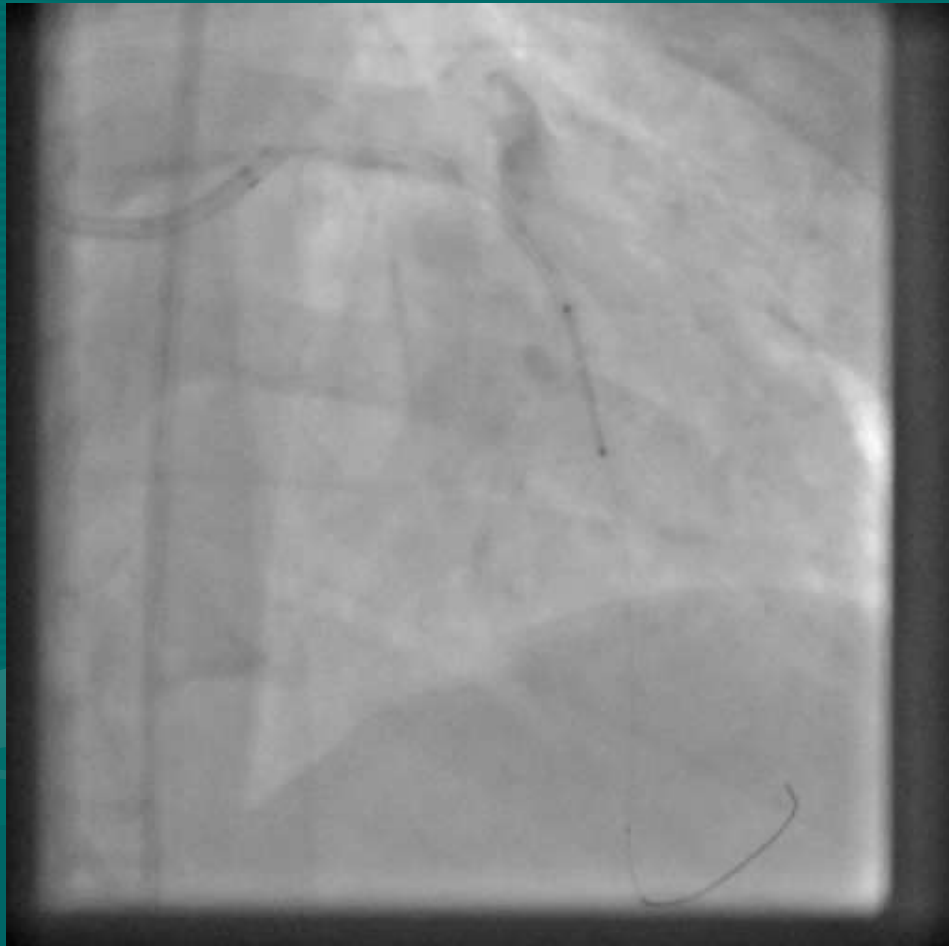
BALLOON INFLATION



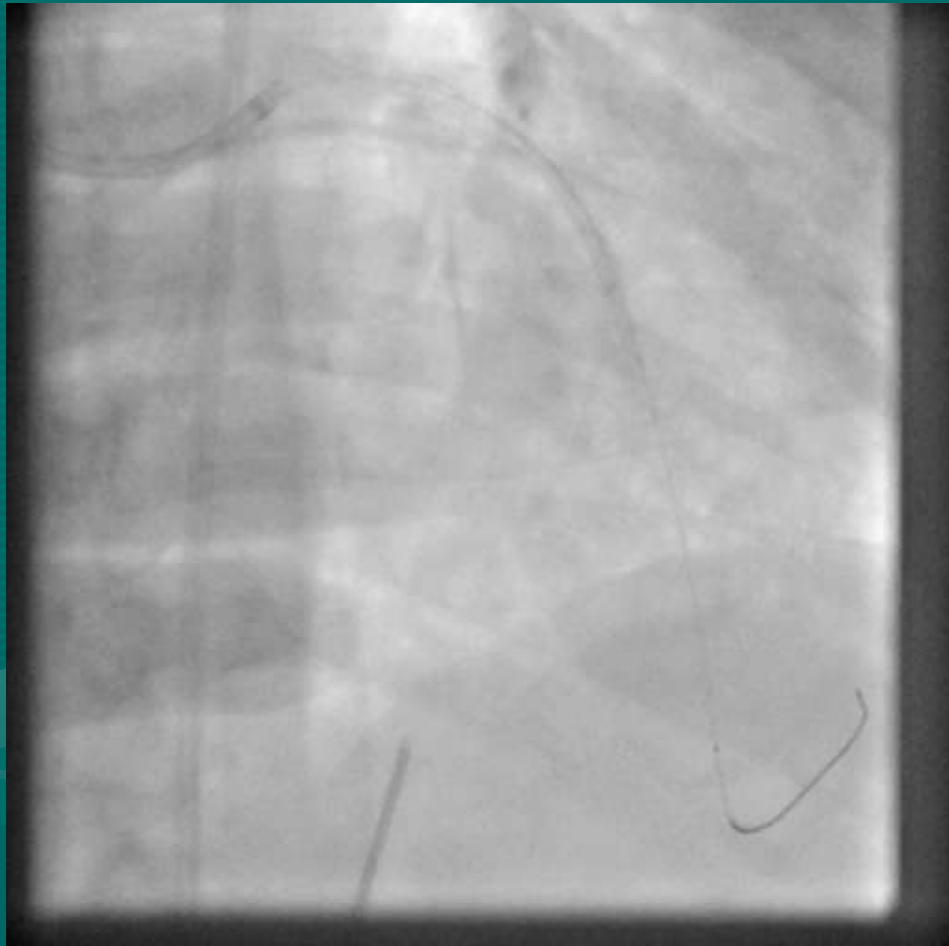


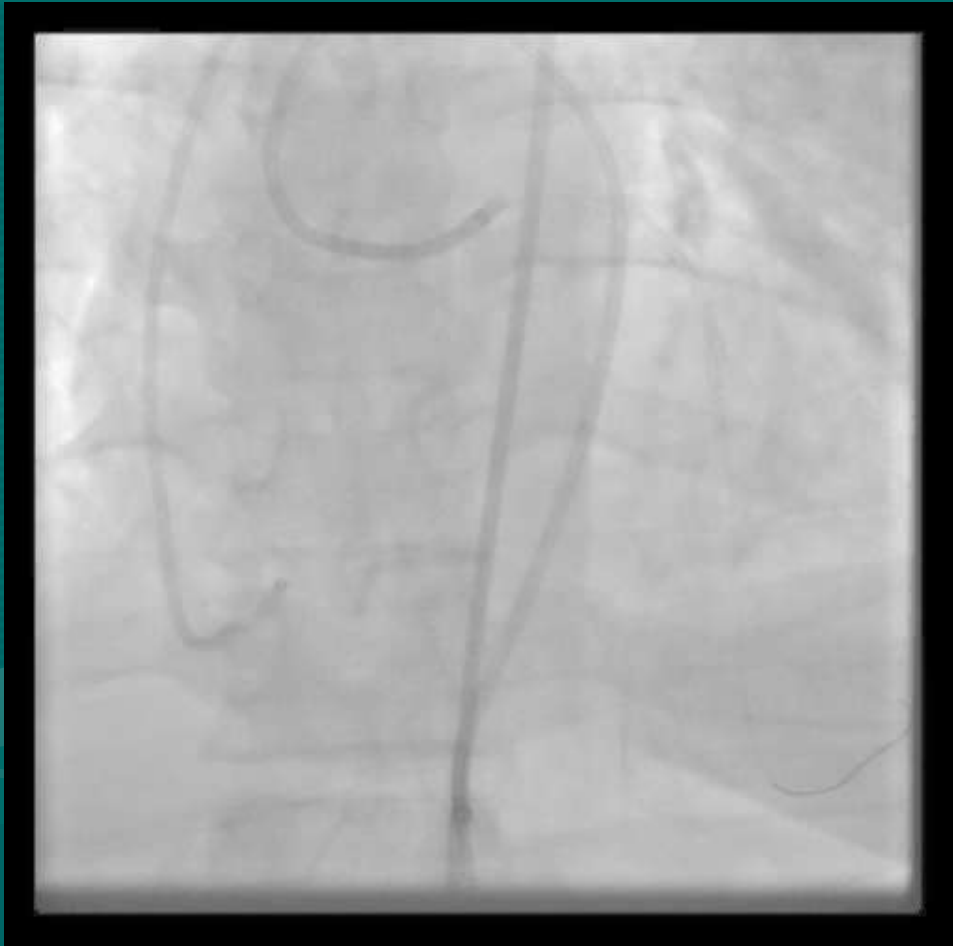

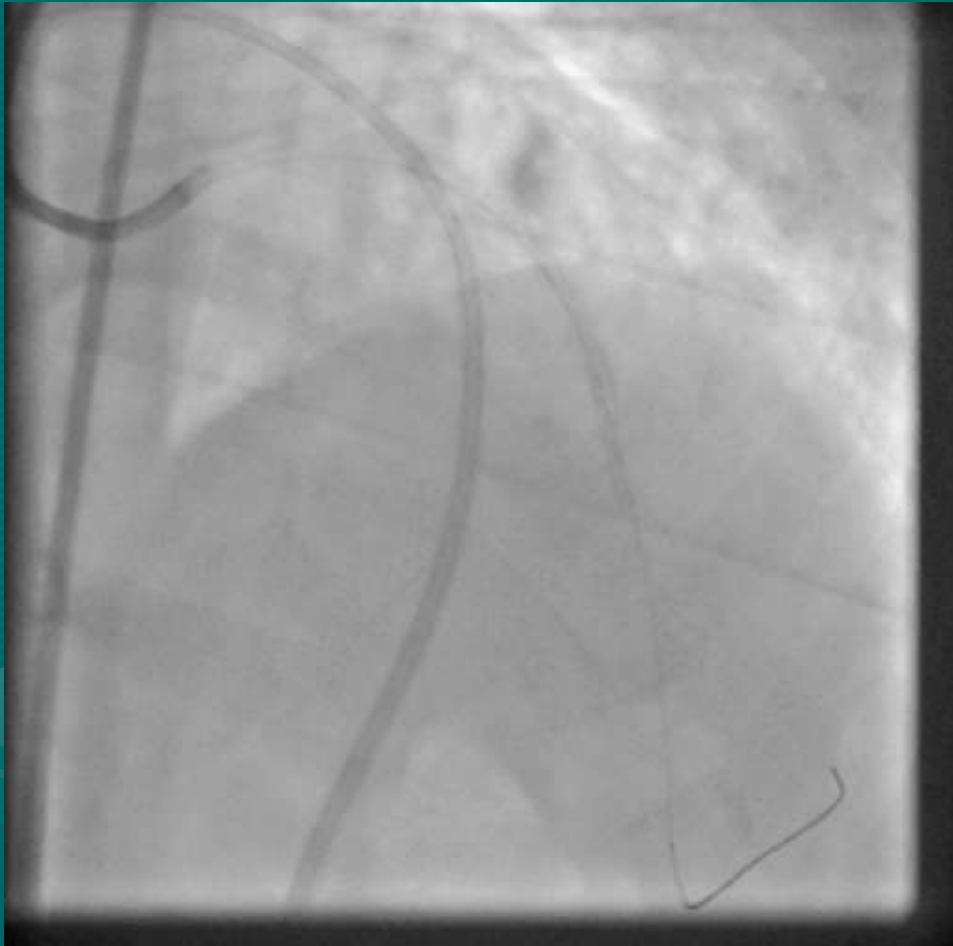
2.5 x 18 XIENCE PRIME

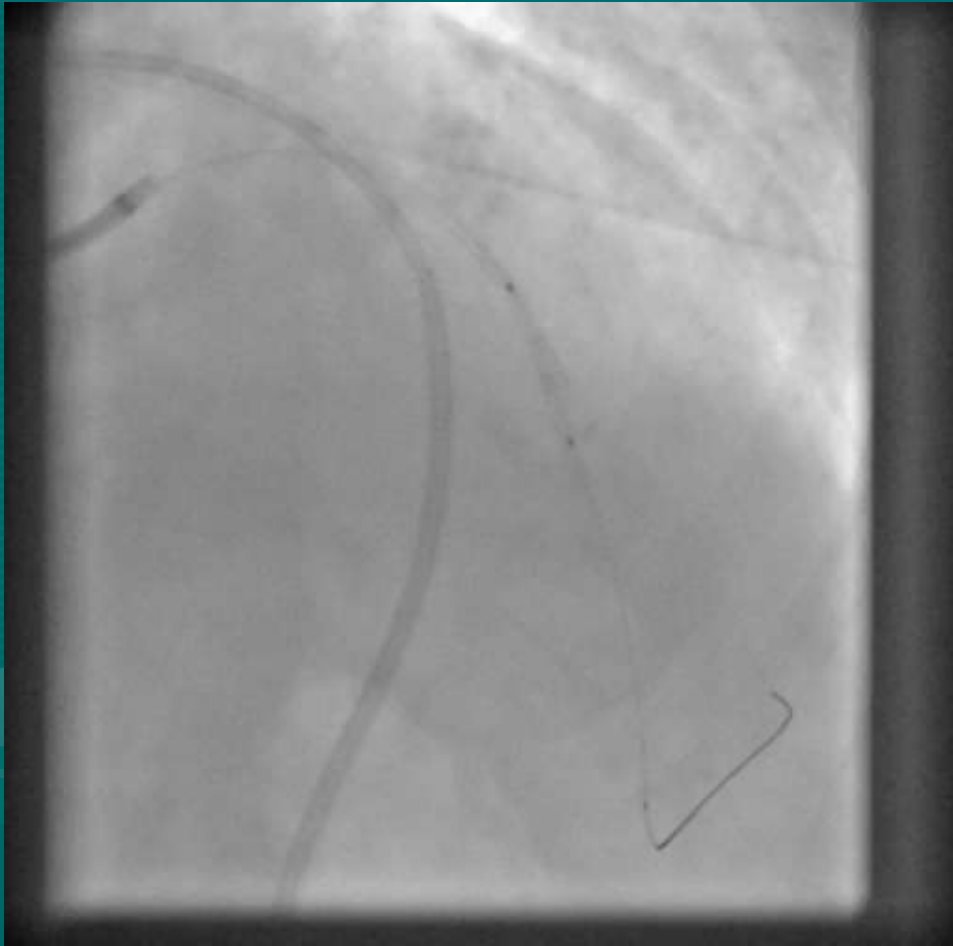


PERICARDIOCENTESIS

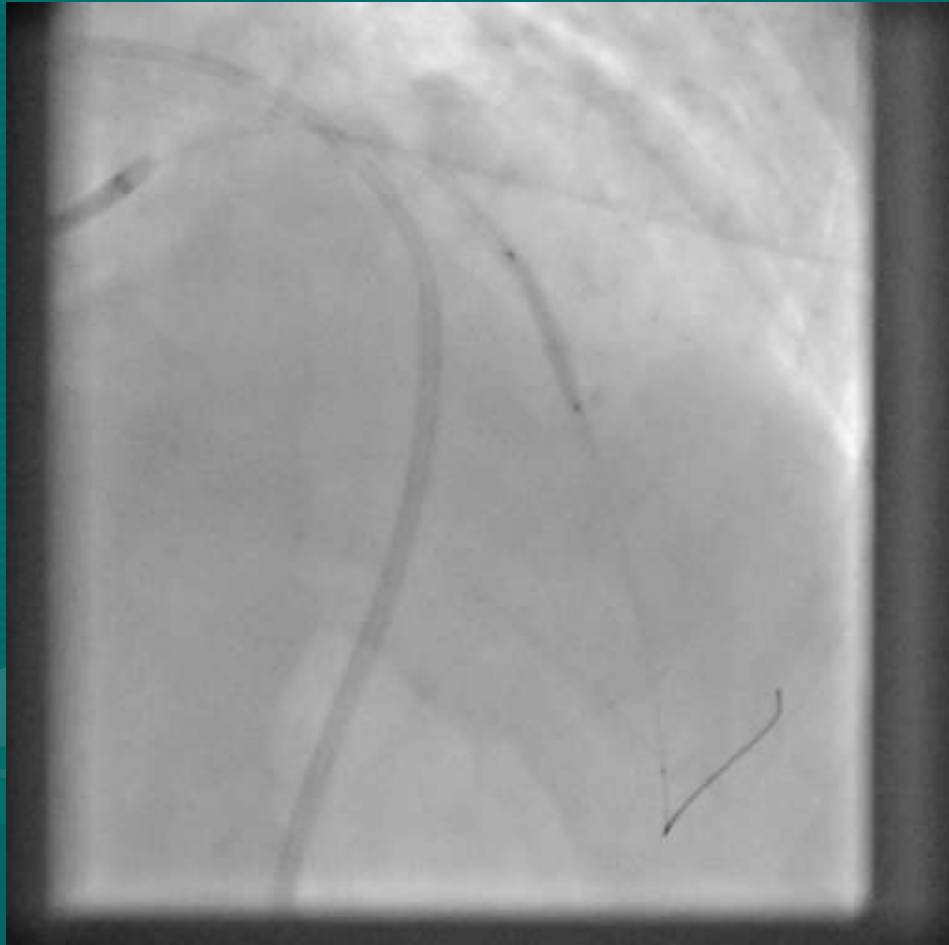




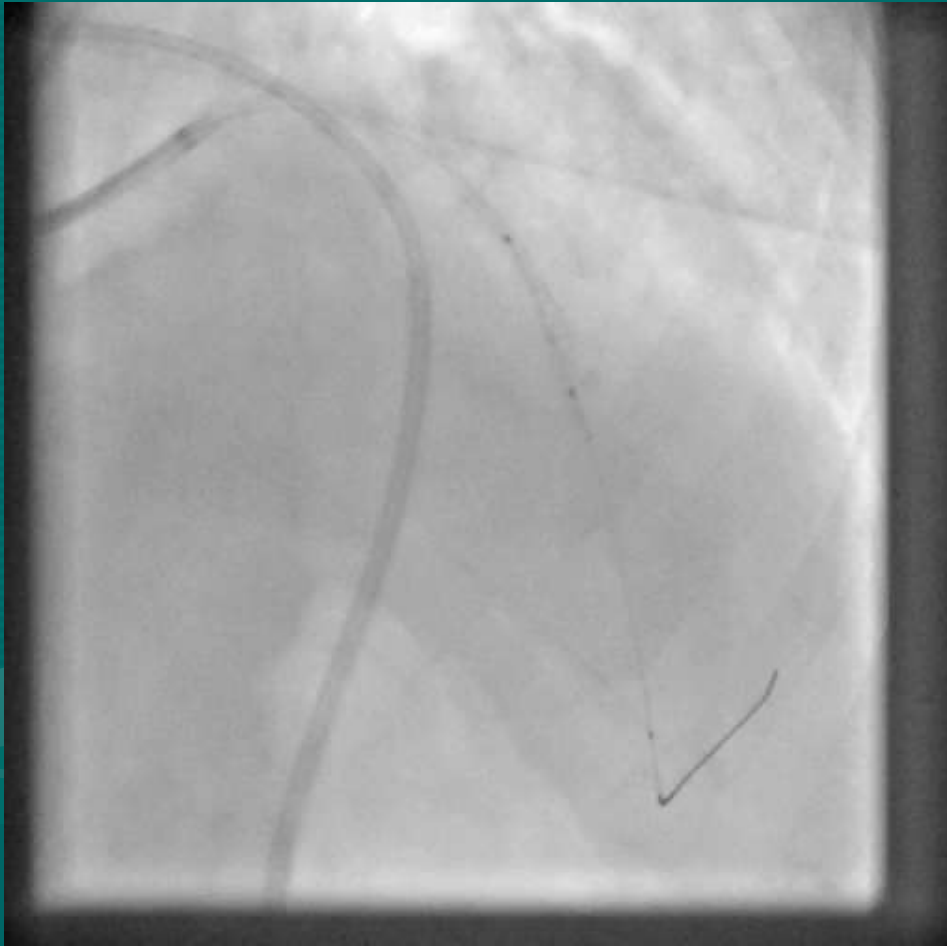




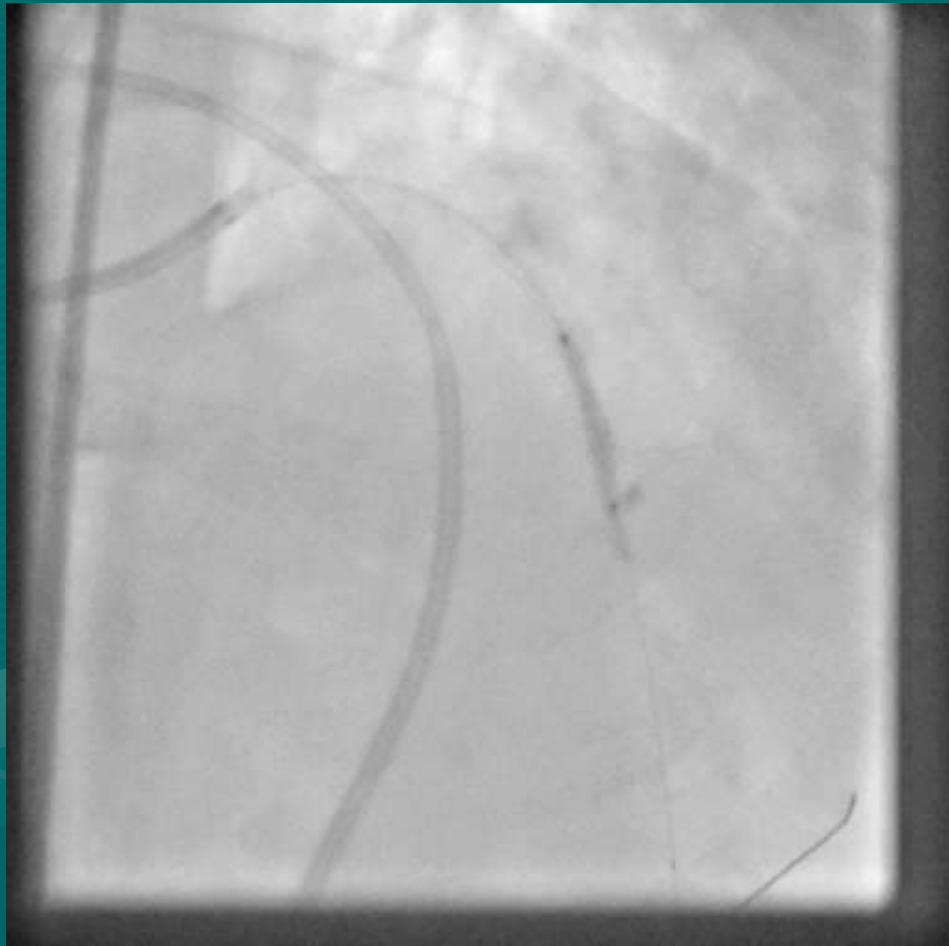
BALLOON INFLATION



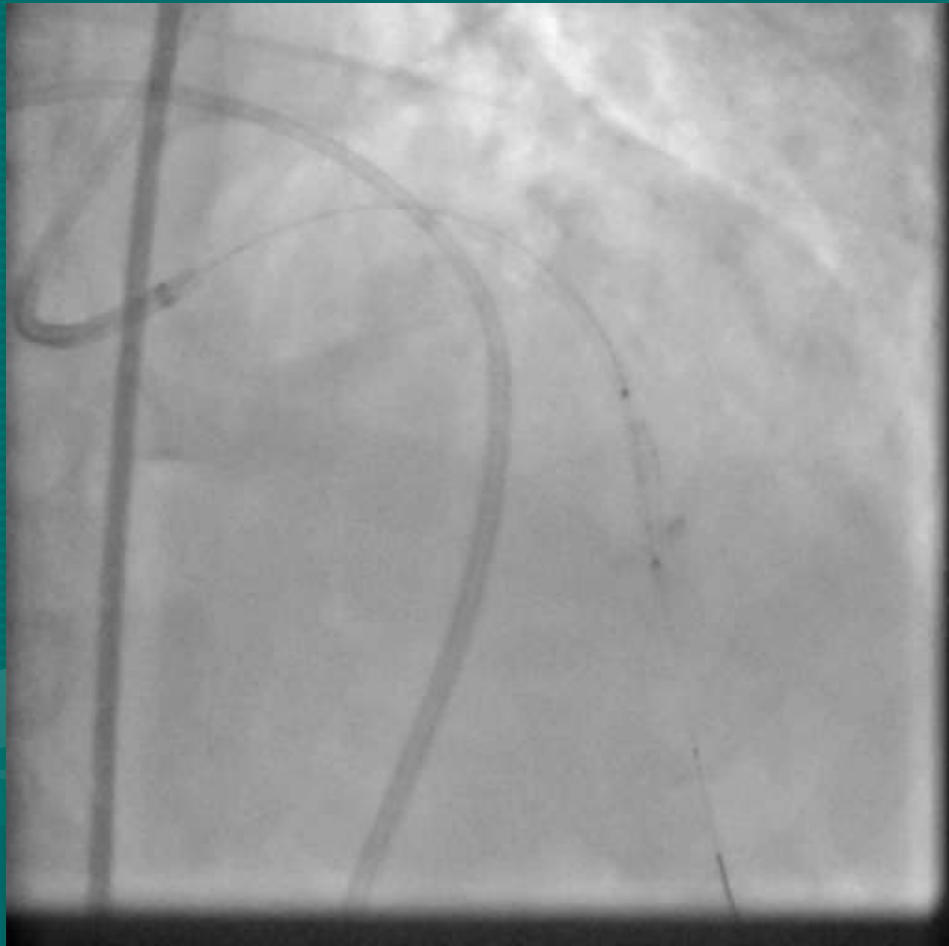WHILE...



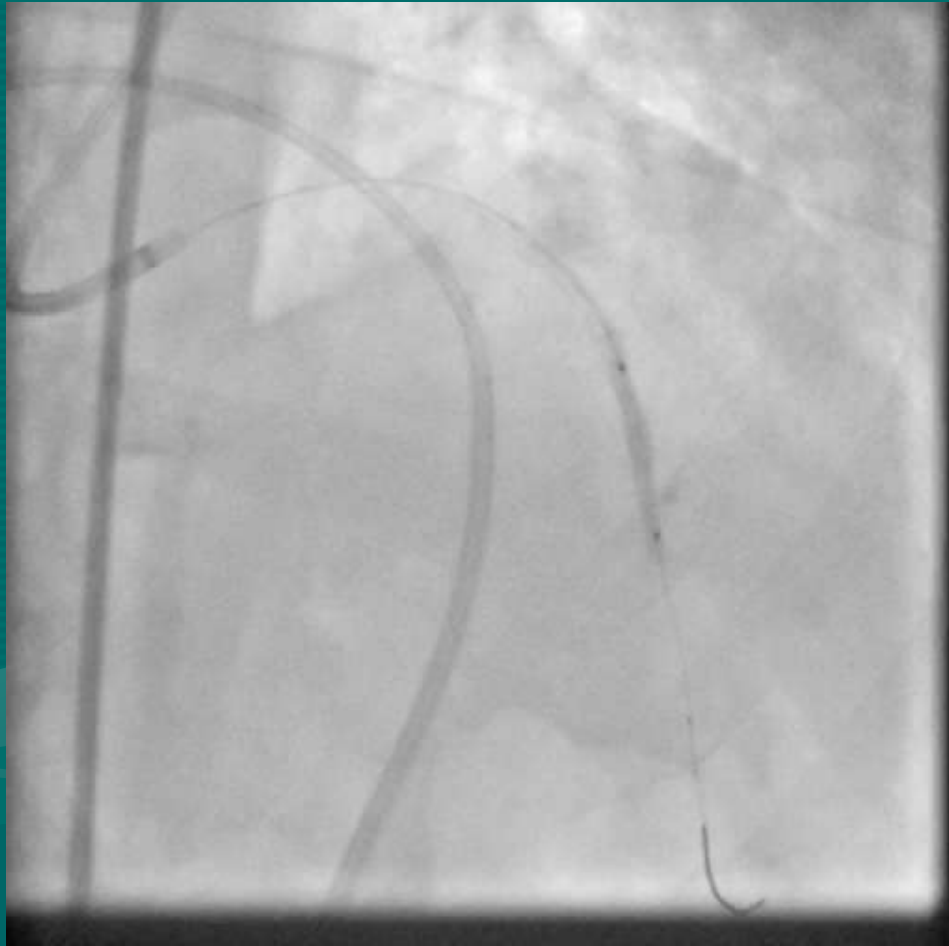
I...



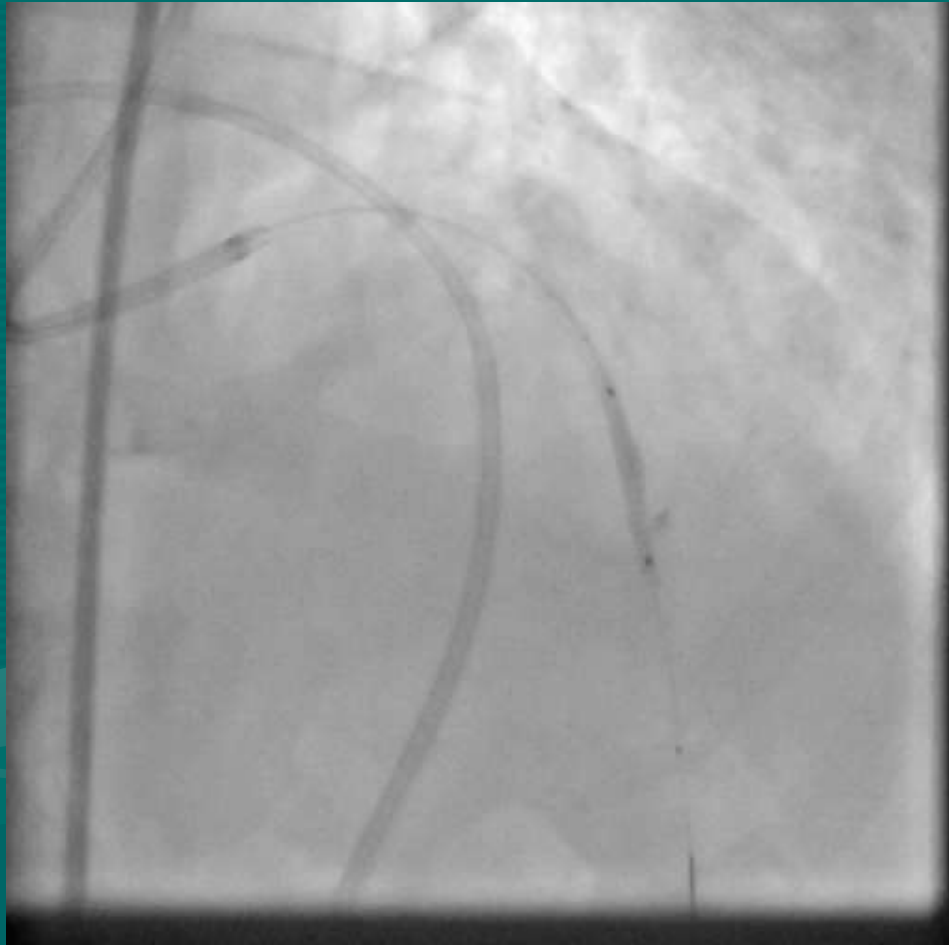WAITED...



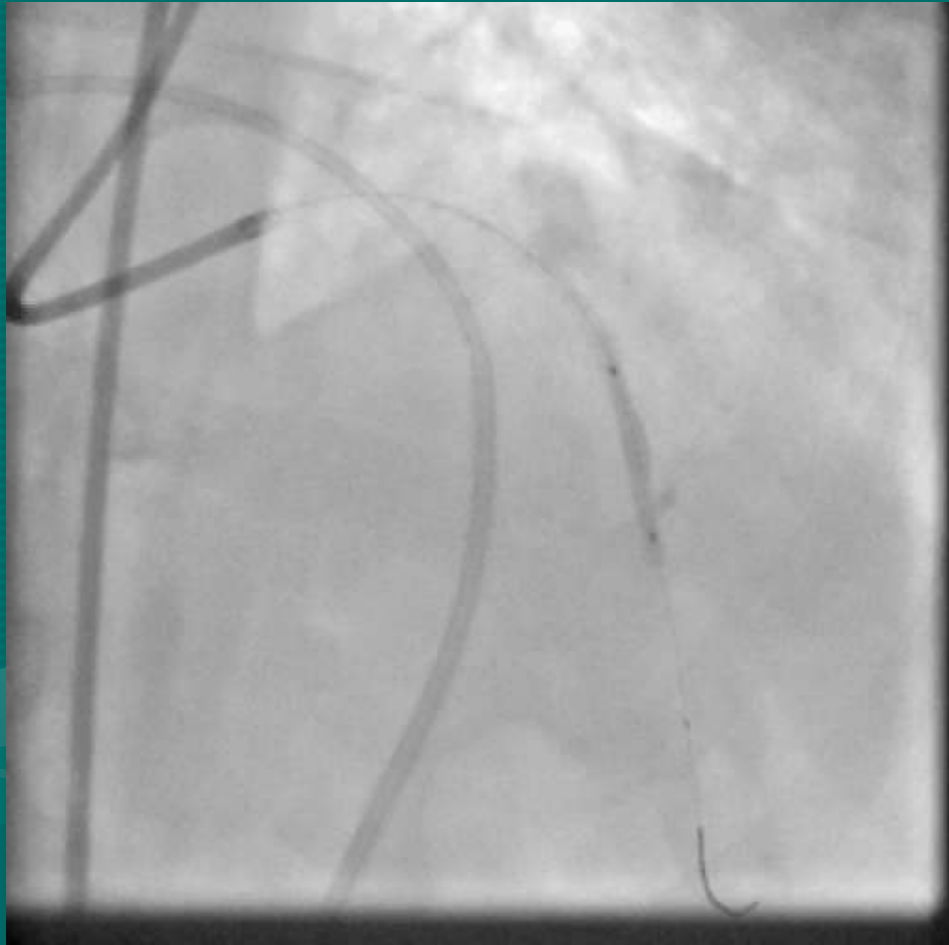PATIENTLY....



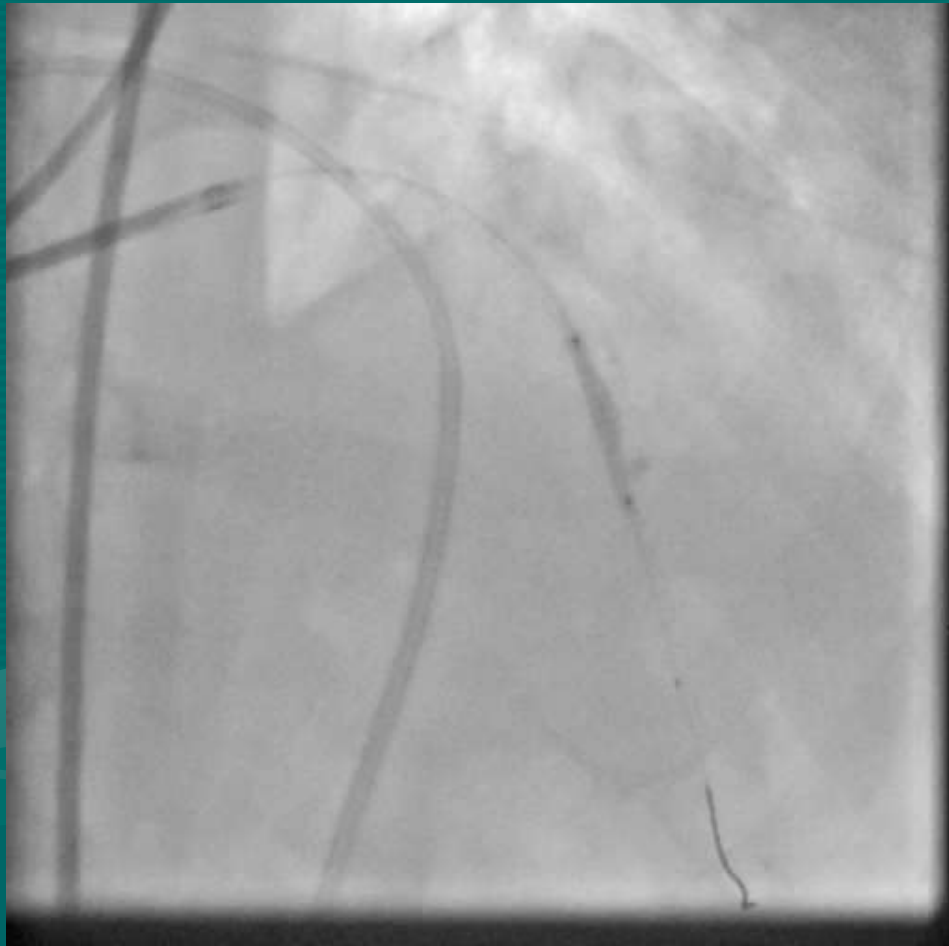
FOR....



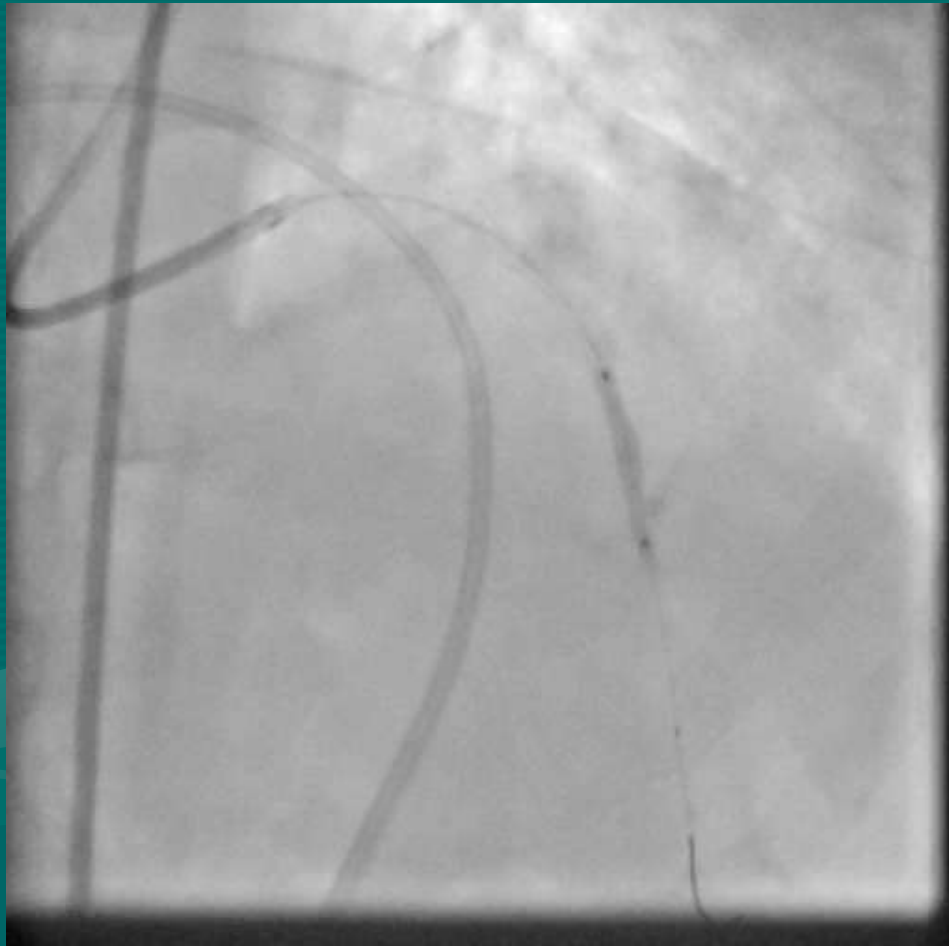
THE....



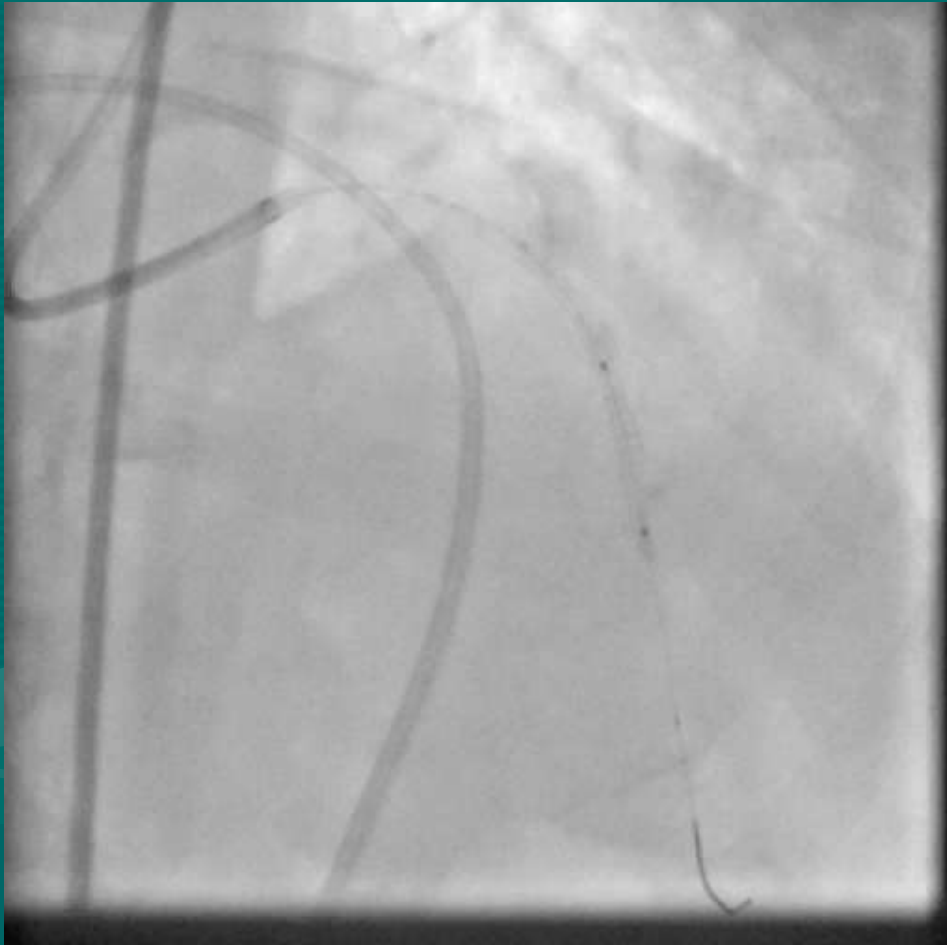
COVERED....



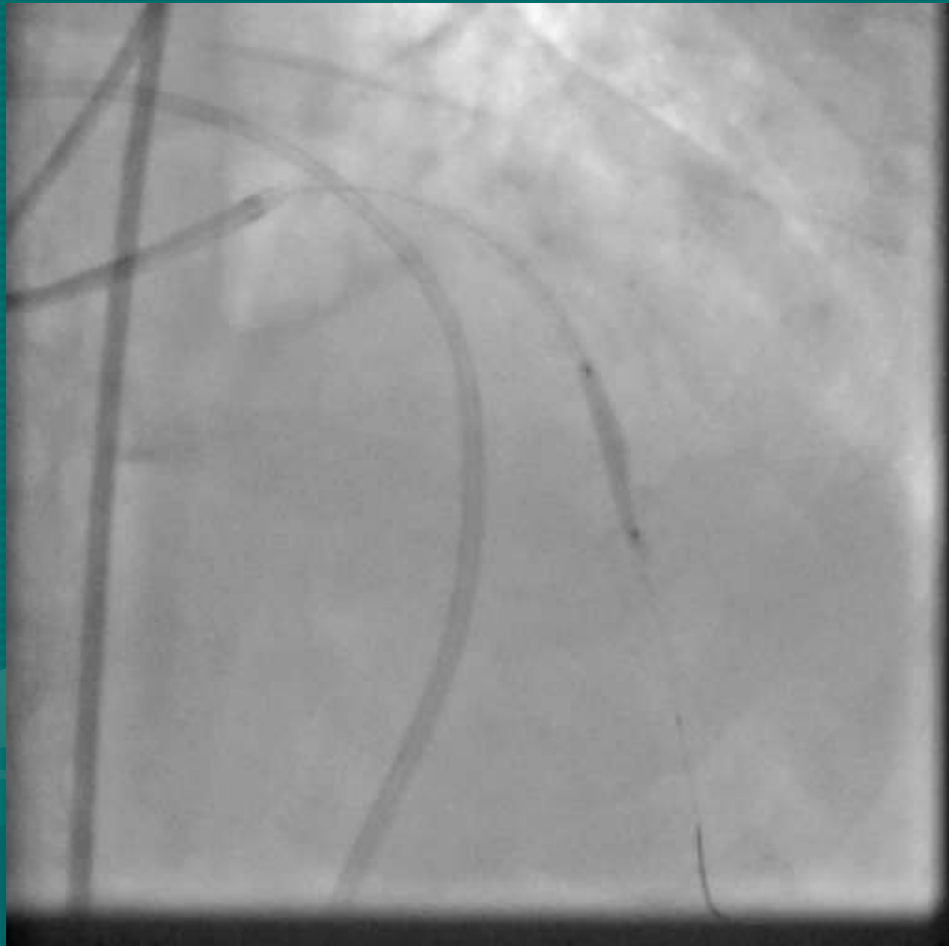
STENT....



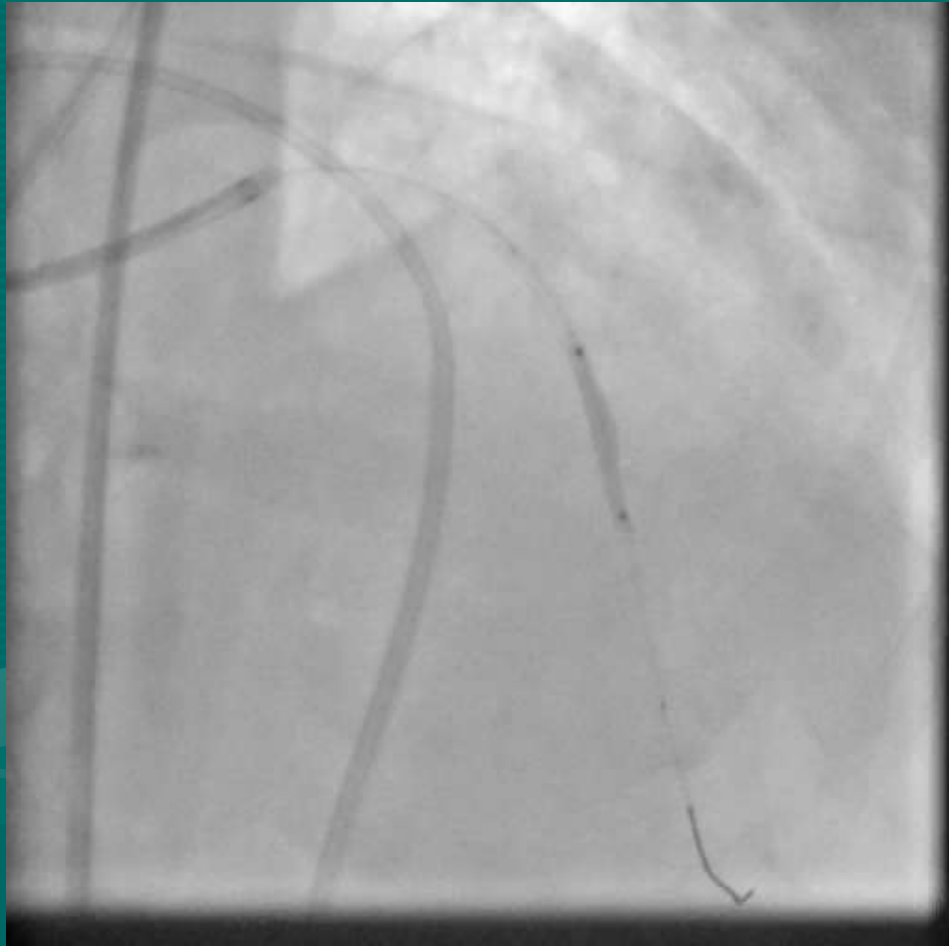TO....



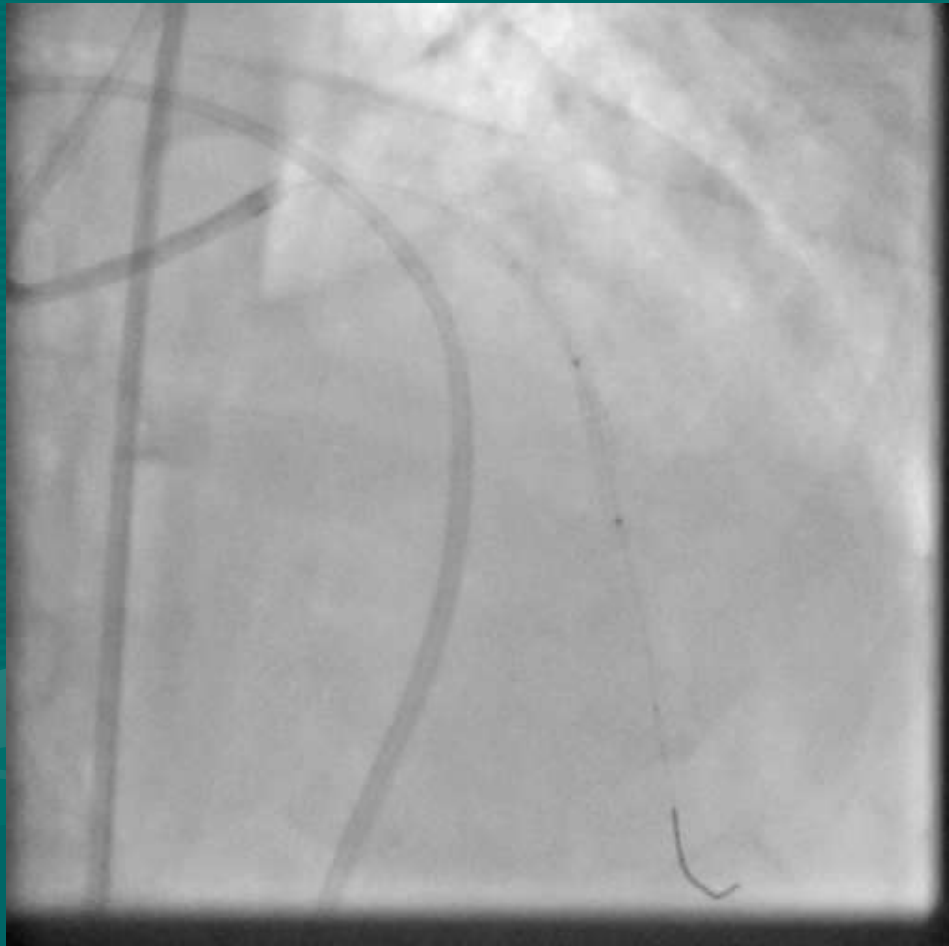ARRIVE.....



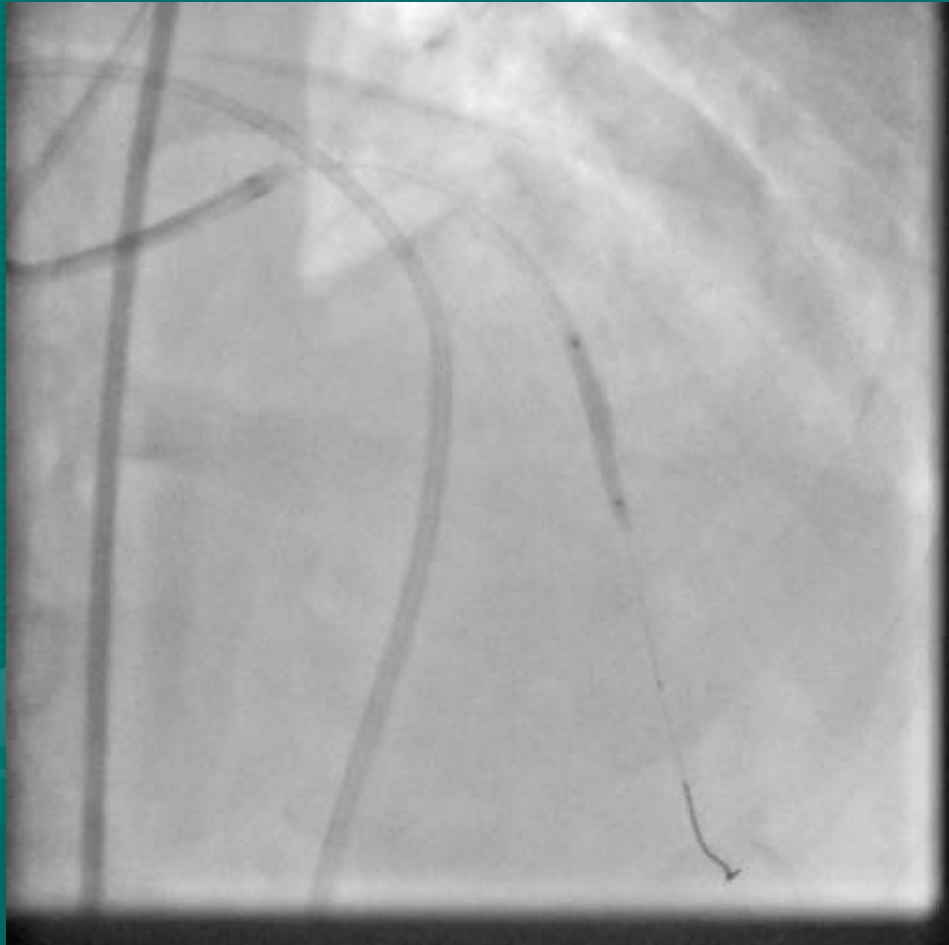FROM.....



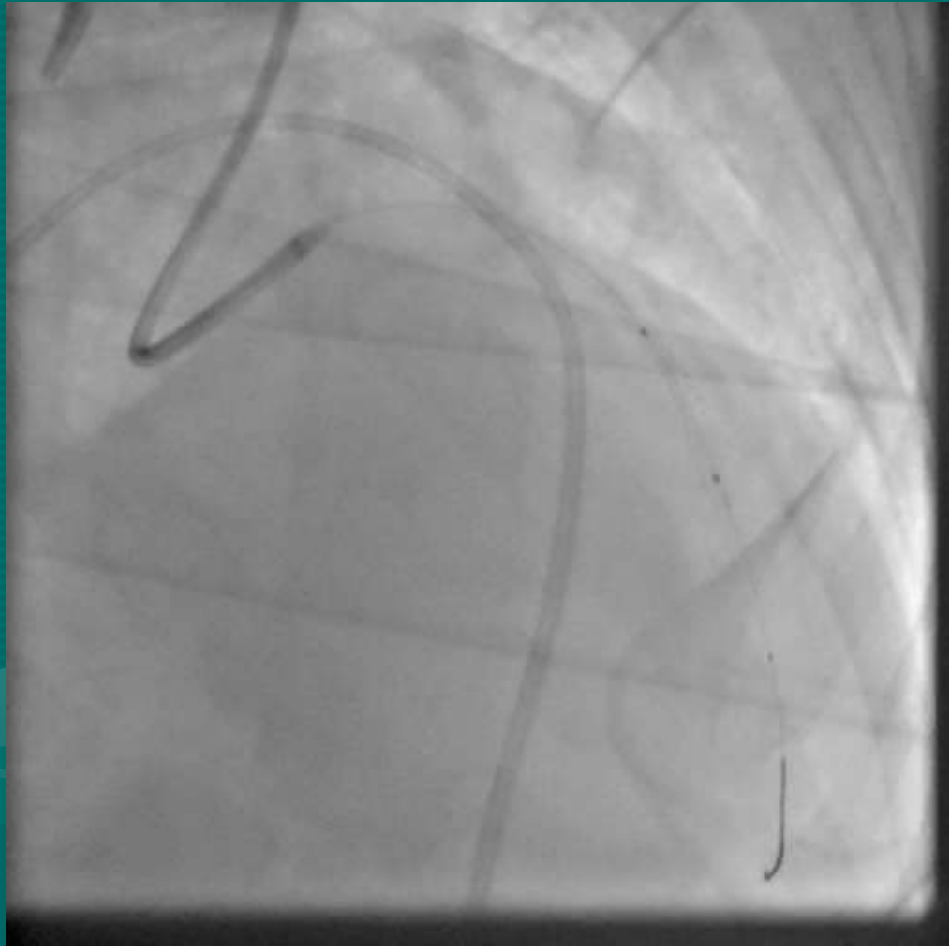
FAR....



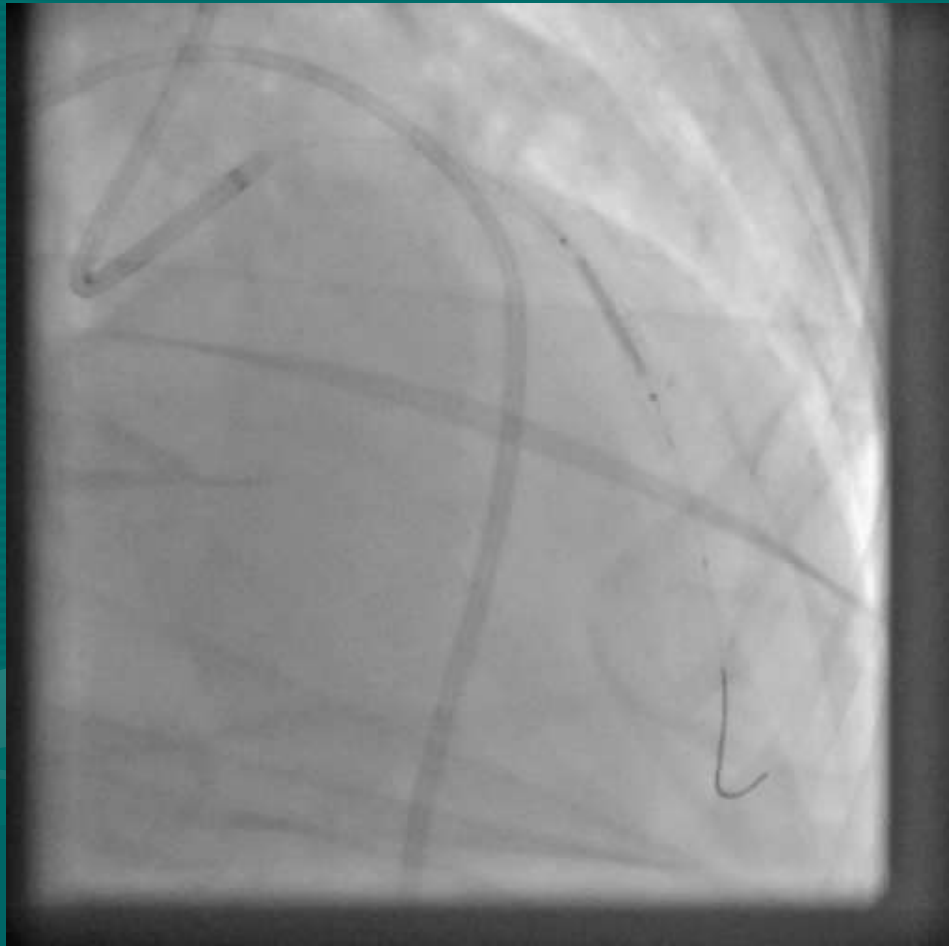FAR.....



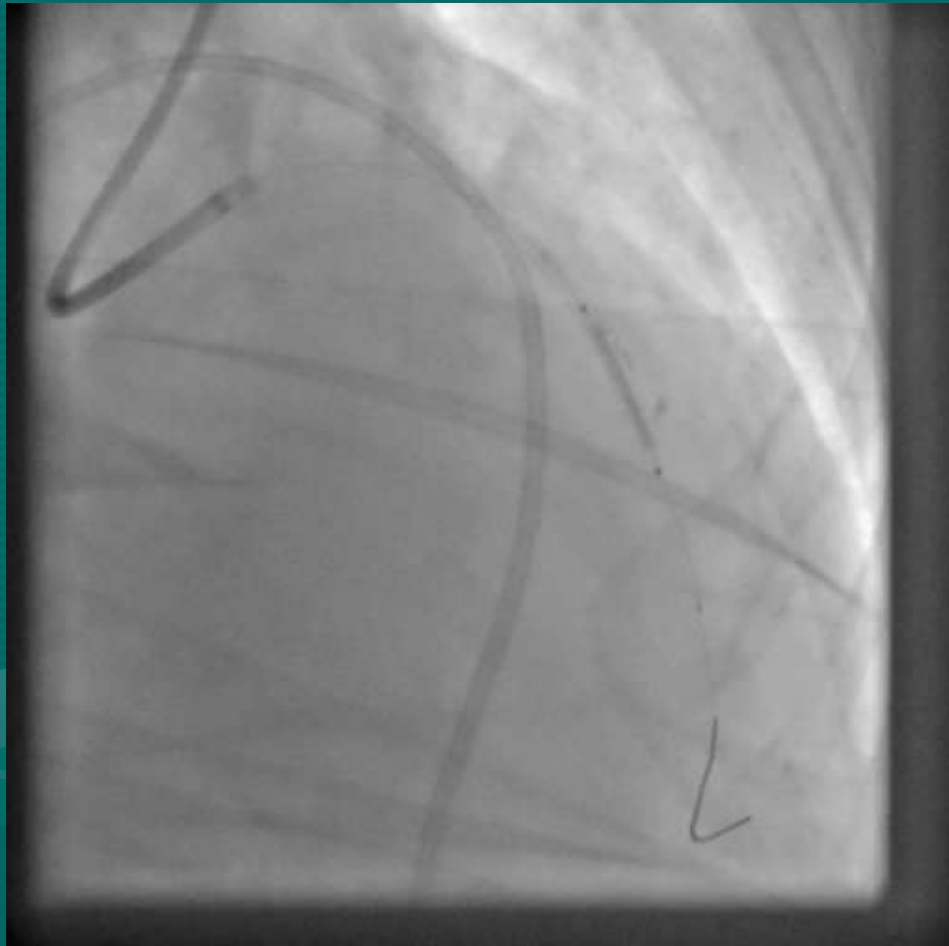
FAR AWAY.....

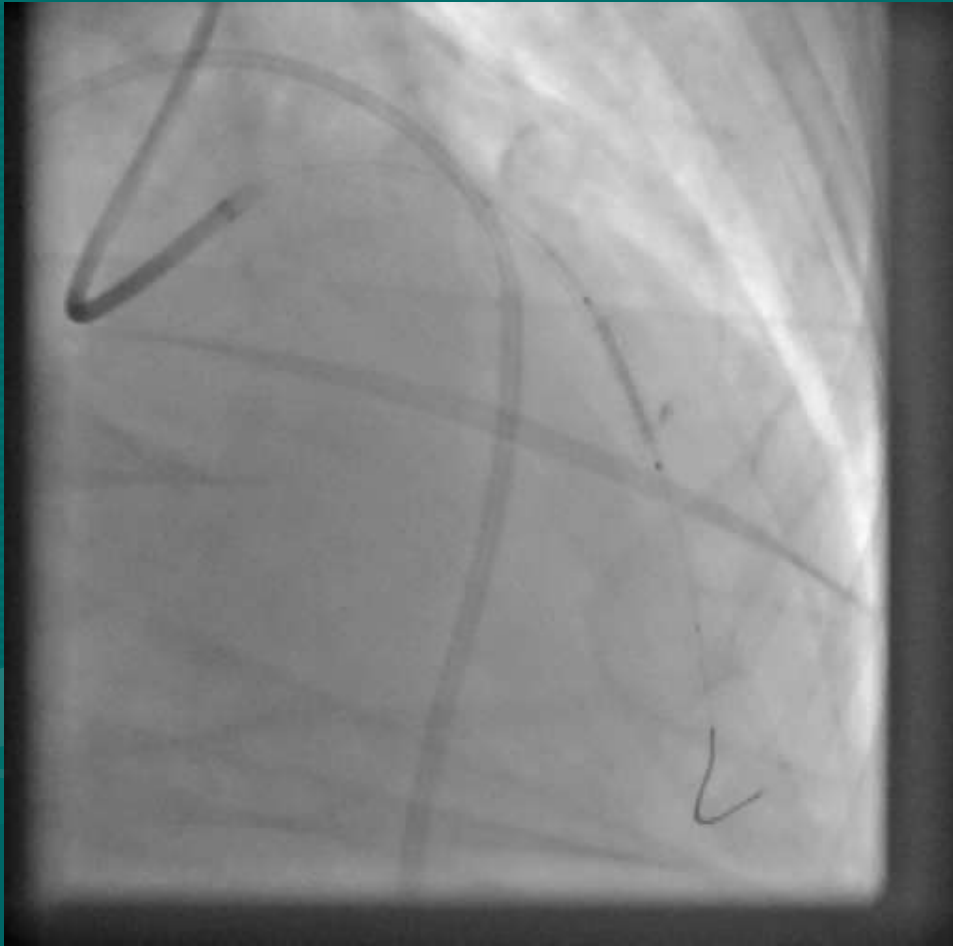


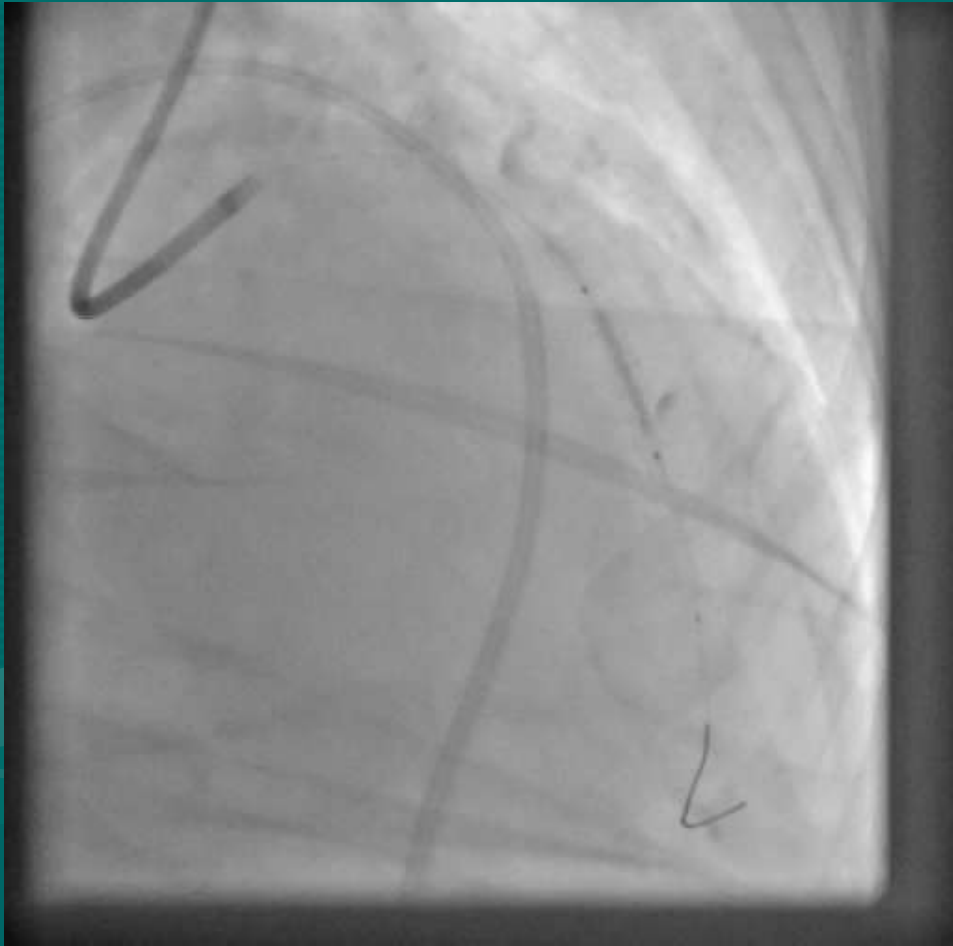
3.0 x 15 COVERED STENT



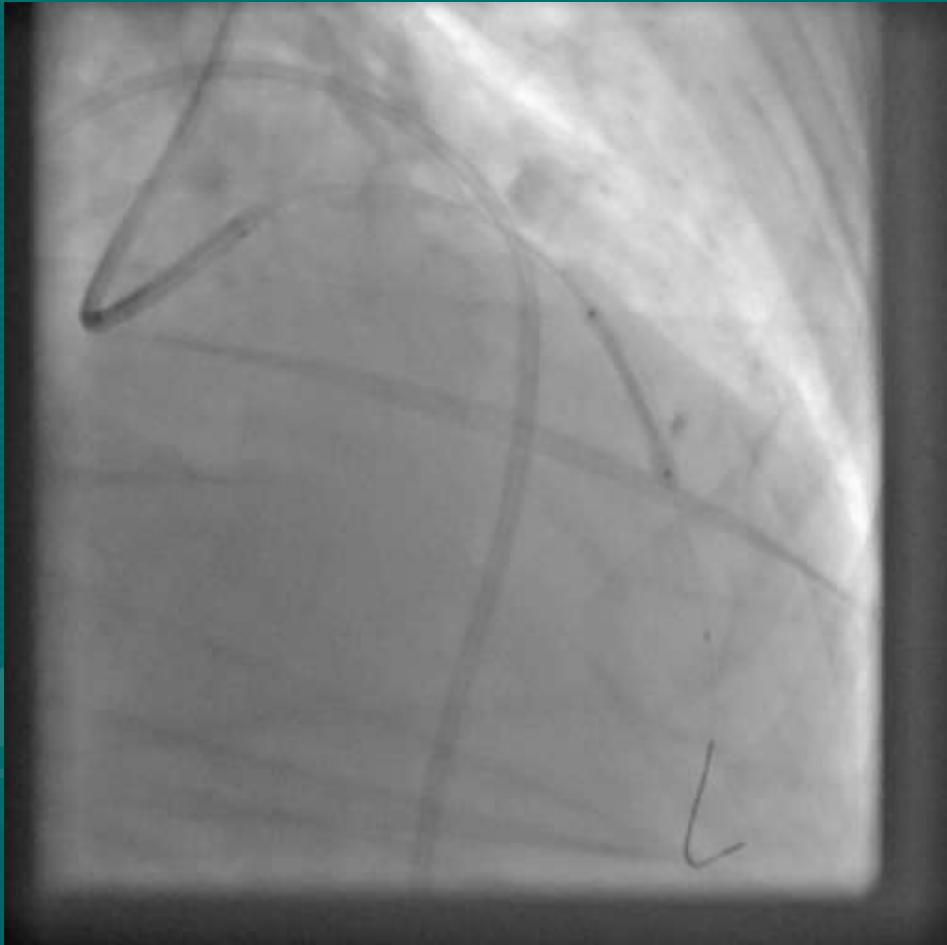
POSITIONED



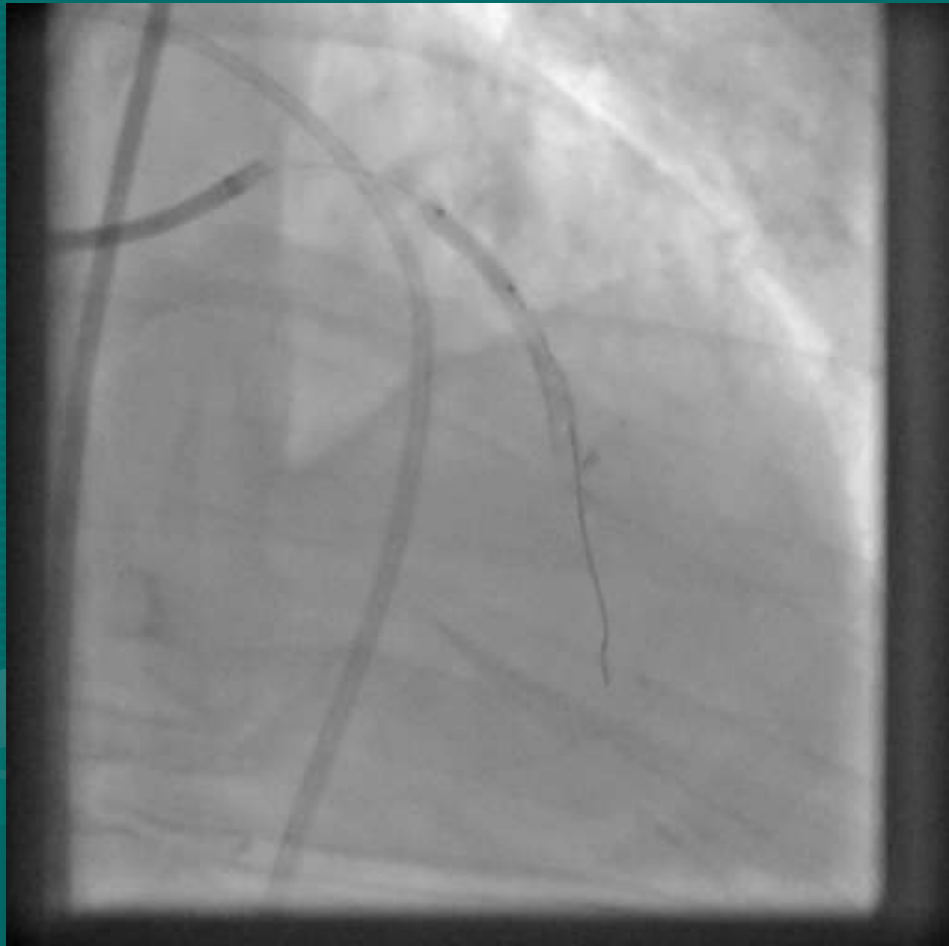

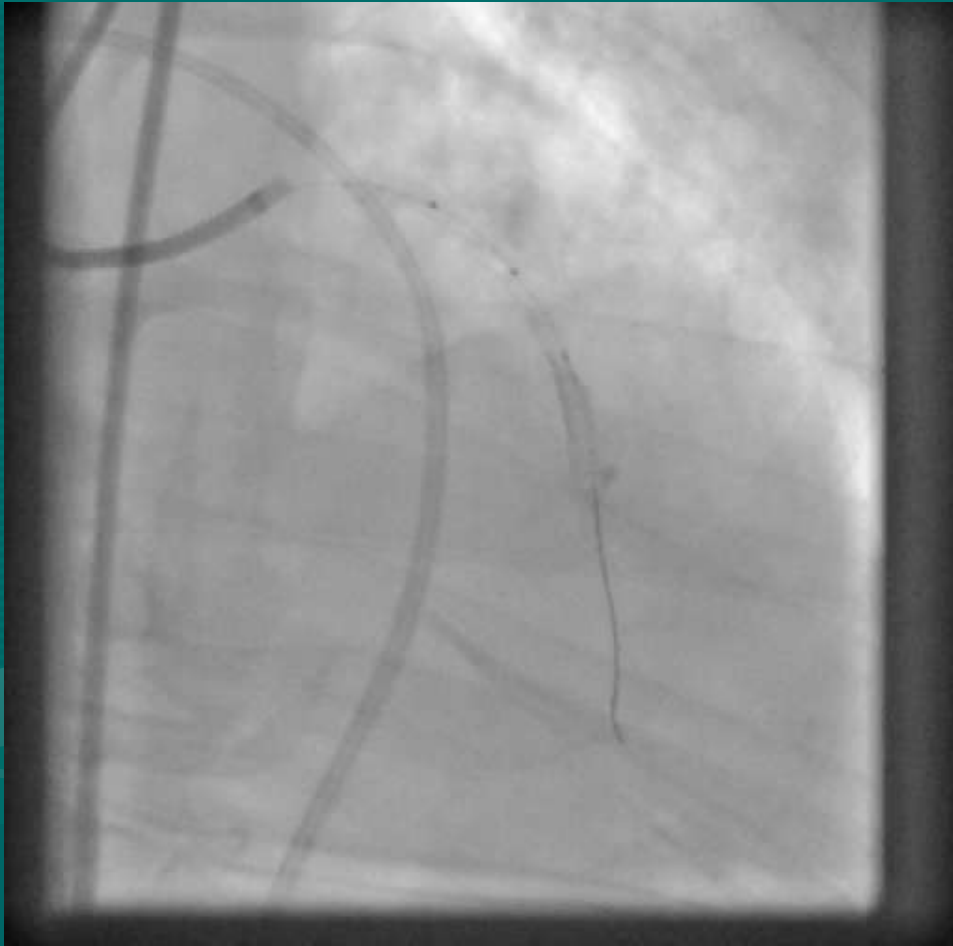


DEPLOYED

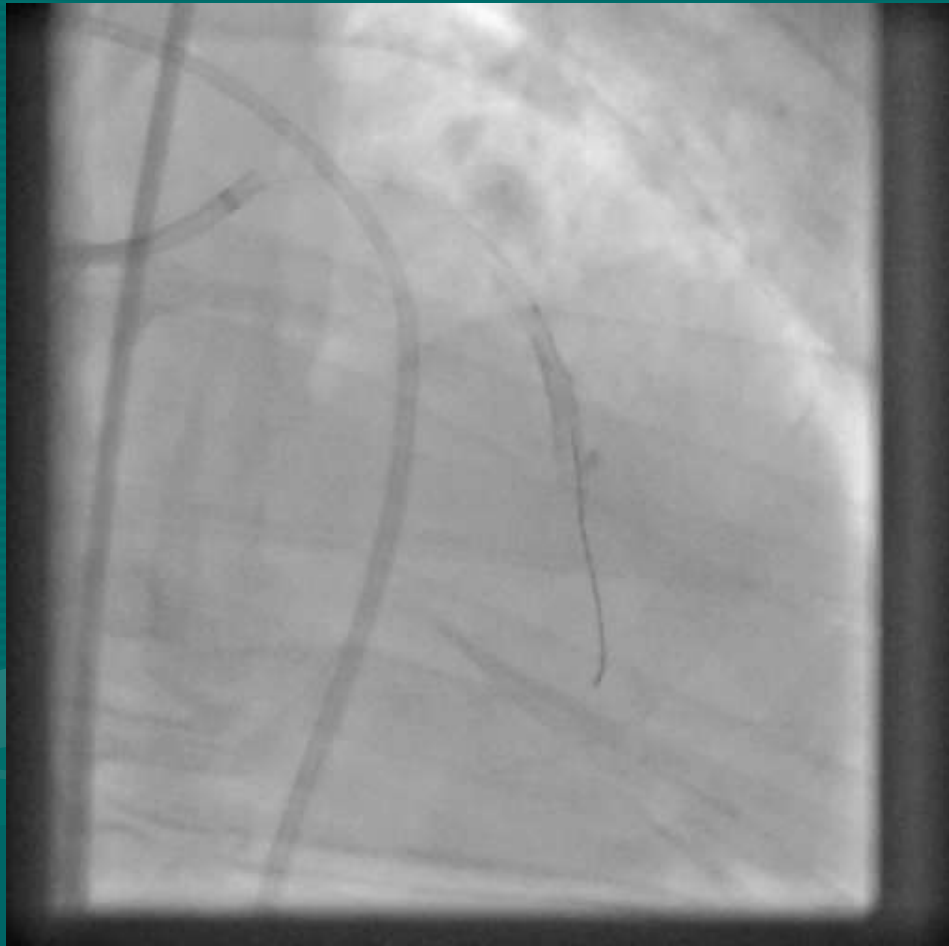


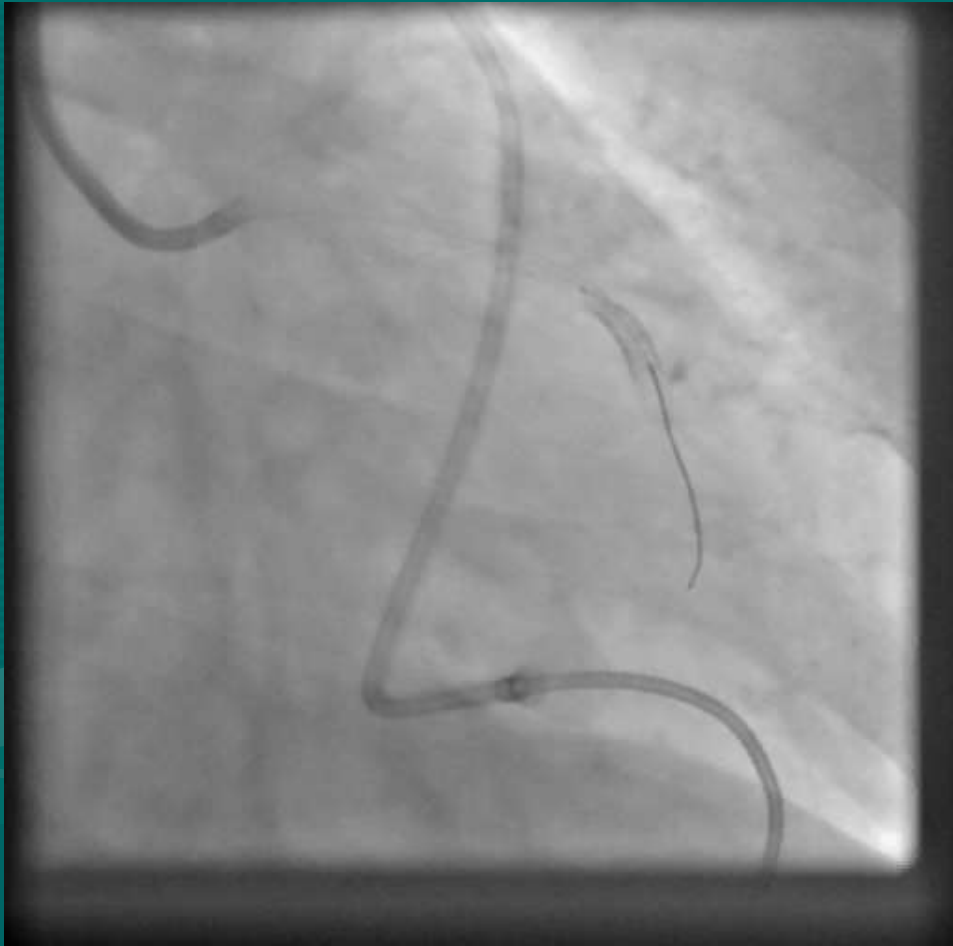POST DILATED

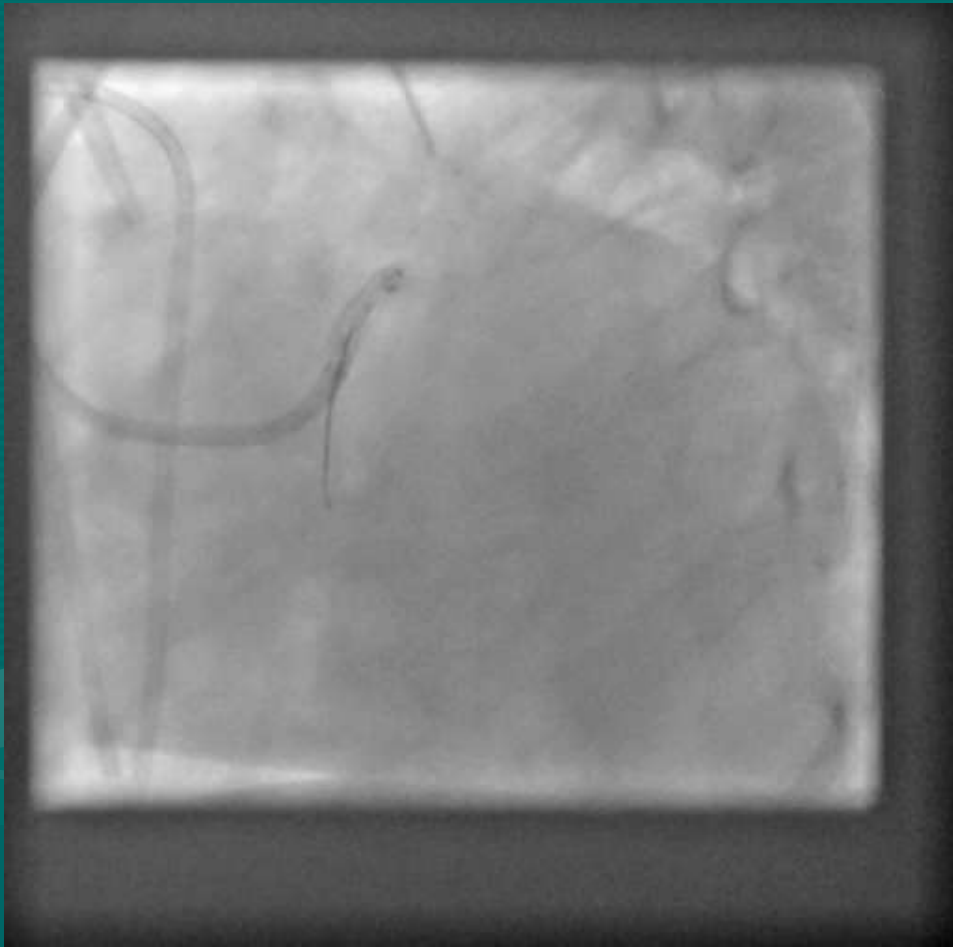


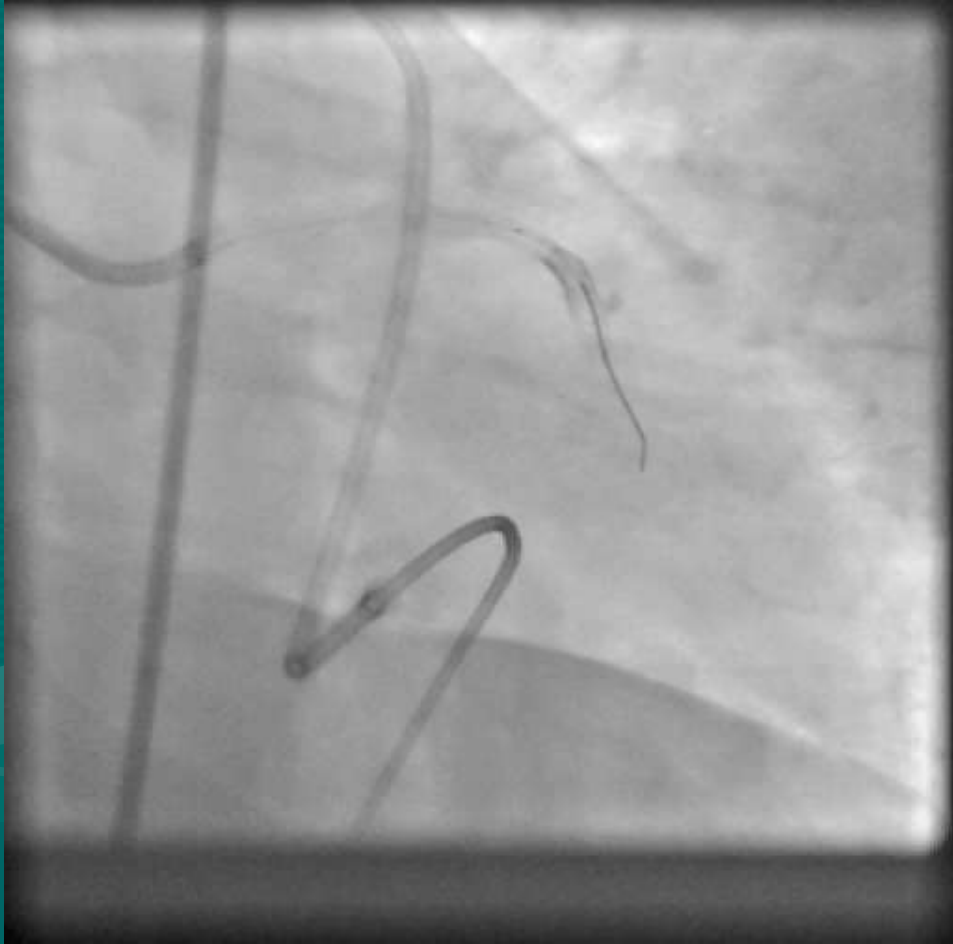

NEW ISSUE

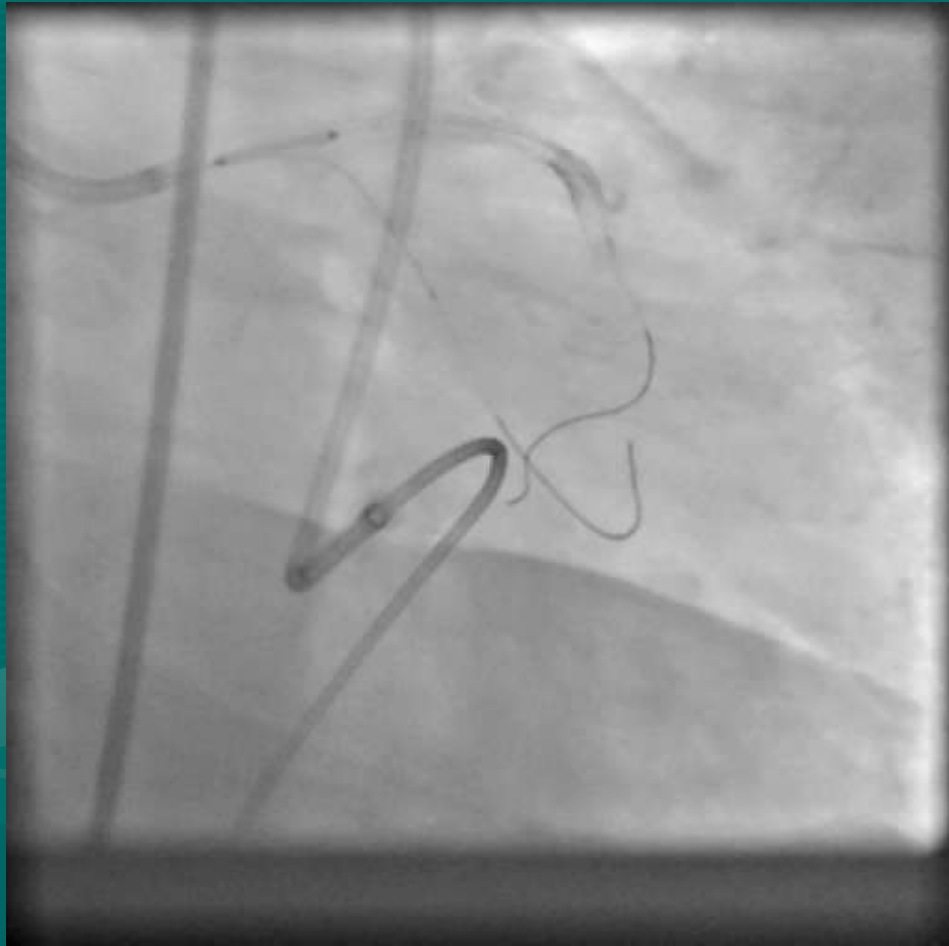


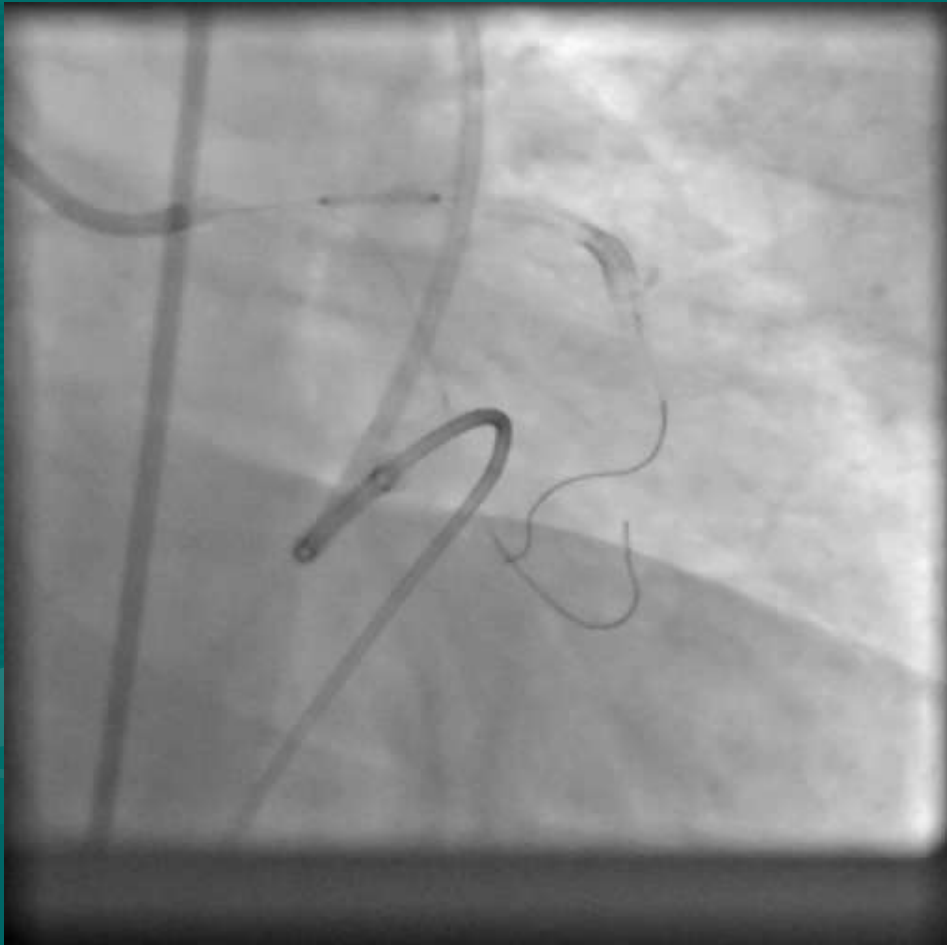


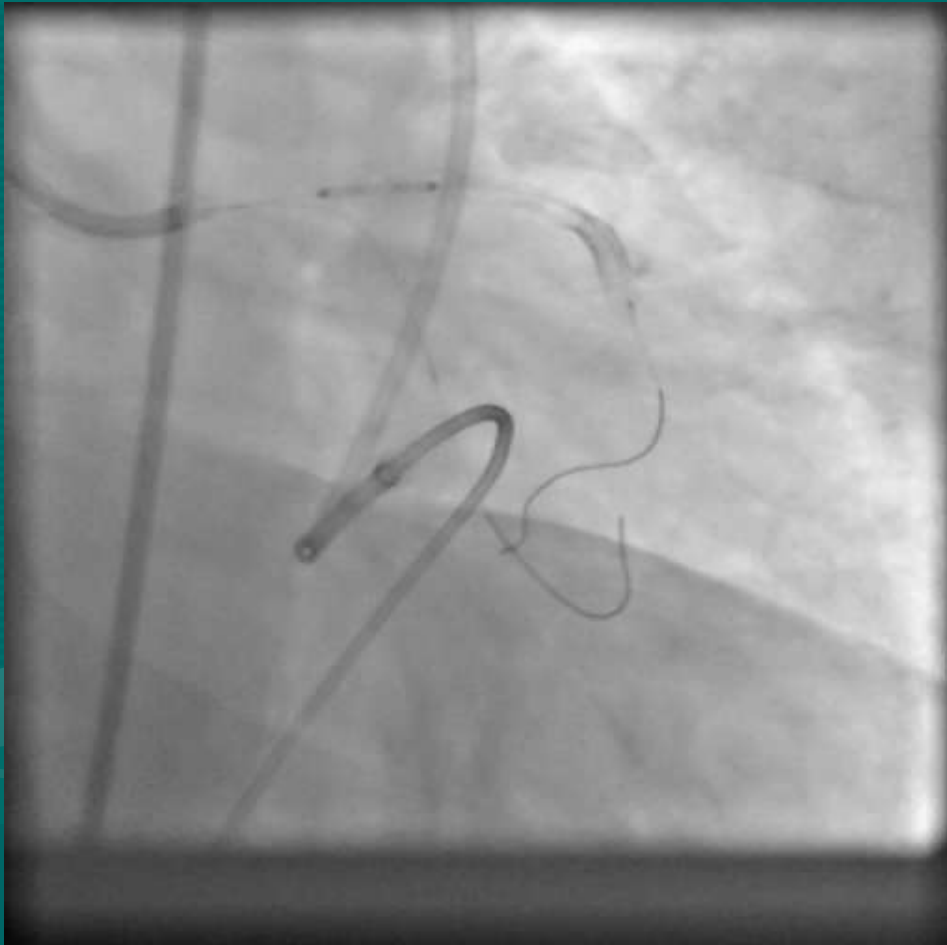

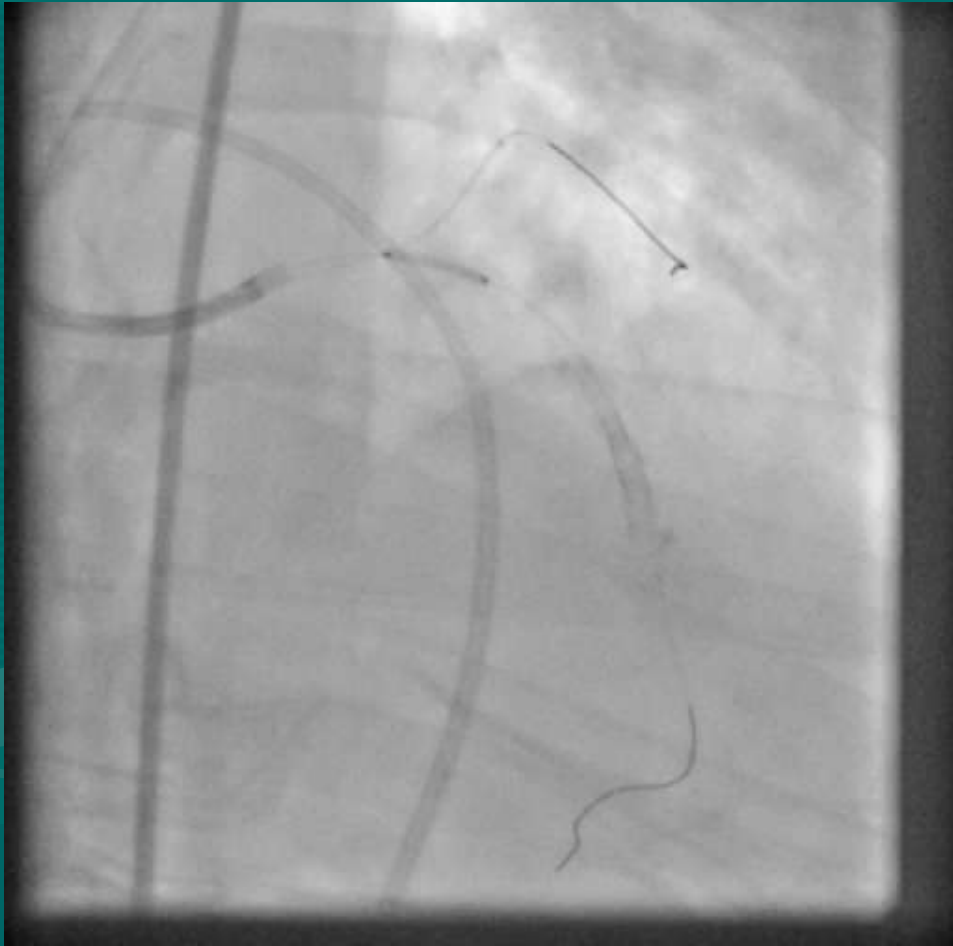


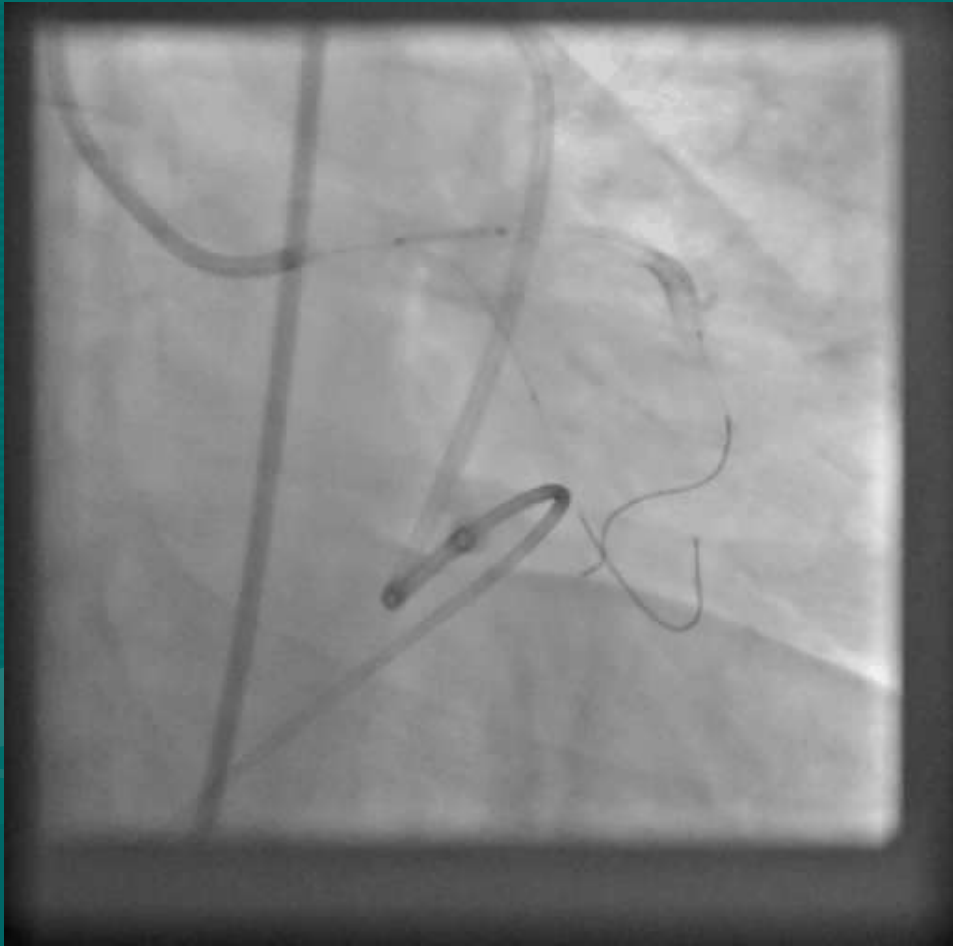
3.5 X 12 XIENCE V

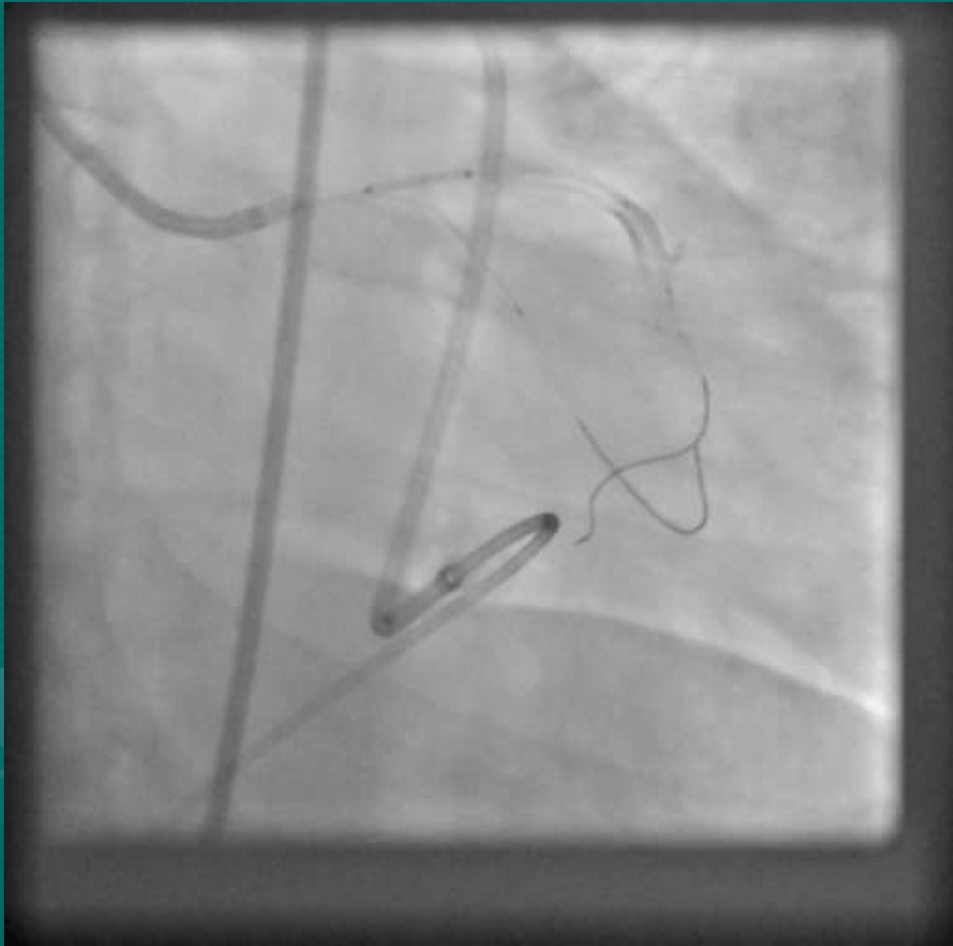


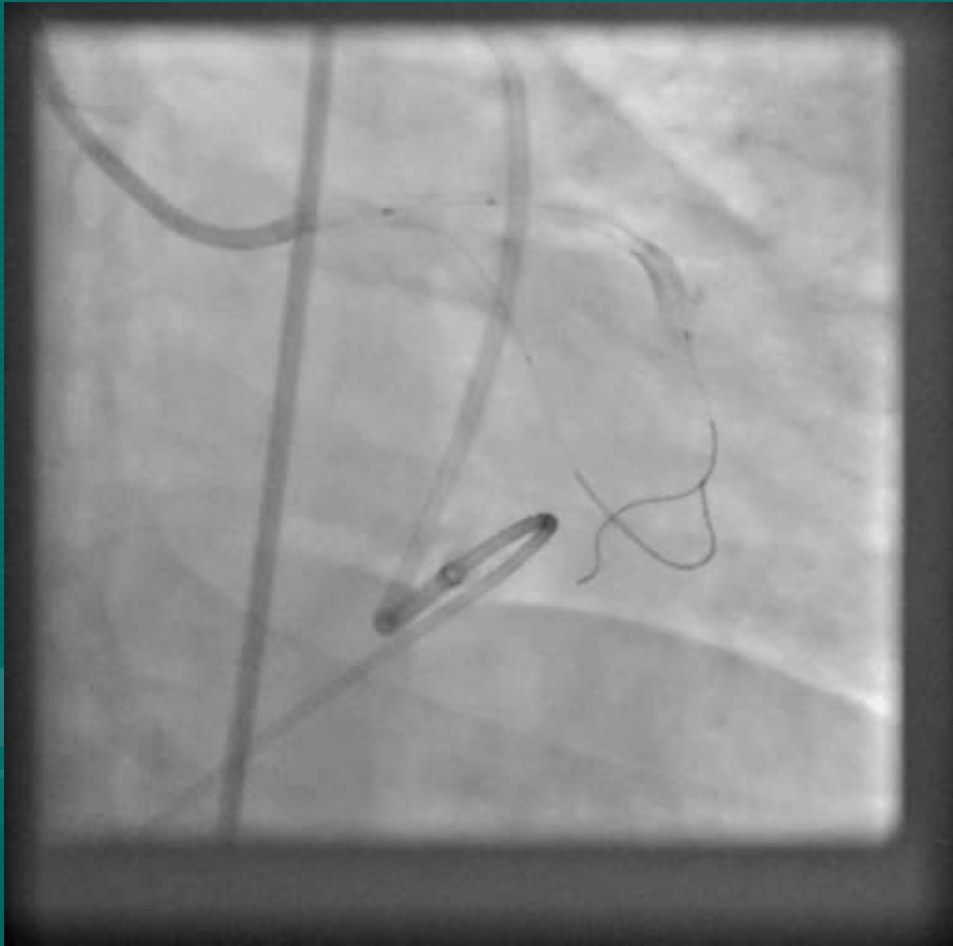


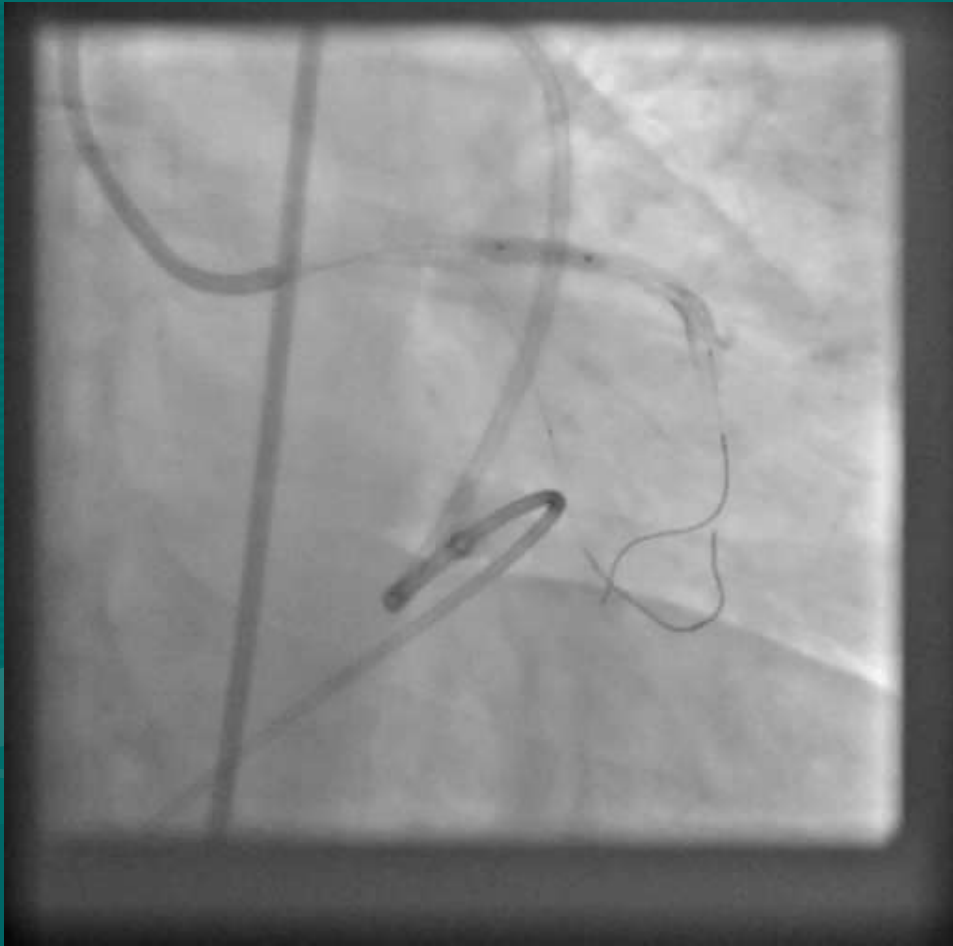


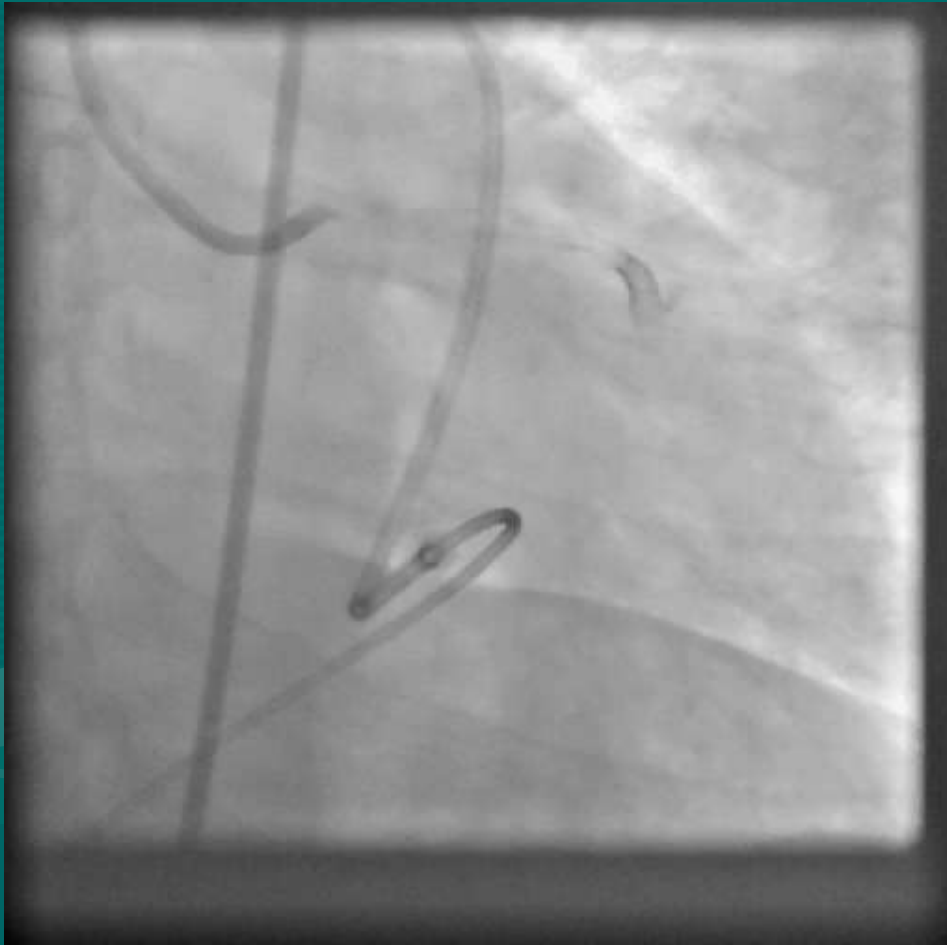









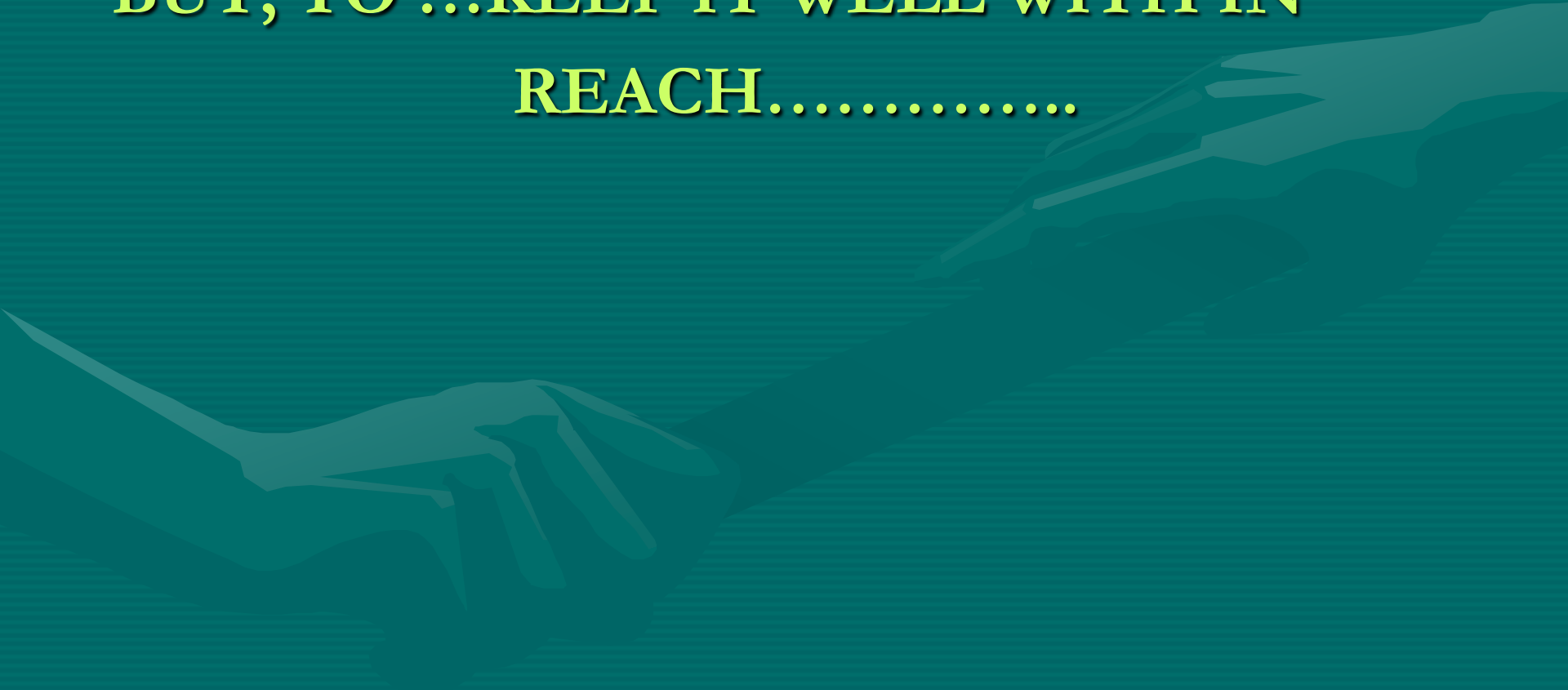


“MY FIRST HAND EXPERIENCE HAS
TAUGHT ME, **NOT** TO ALLOW THE
COVERED STENT TO BE...
A NEEDLE IN THE HAY STACK !!!”

**BUT, TO ...KEEP IT WELL WITH IN
REACH.....**



...AT LEAST IN THY **NEIGHBOUR'S**
CATH LAB....



THANK YOU VERY MUCH

